

TEK AKCİĞER VENTİLASYONUNDA ZOR HAVAYOLU

Doç. Dr. Tülay ŞAHİN

18. Kış Sempozyumu

1-4 Mart 2012- ULUDAĞ



Prof. Dr. Orhan Toydemir



Zor Havayolu

- Zor maske ventilasyonu
- Zor laringoskopi
- Zor entübasyon
- Zor ekstübasyon

Tek Akciğer Ventilasyonu için

- güvenilir bir havayolunun sağlanması,
- idame ettirilmesi veya
- sonlandırılmasında güçlük

Zor akciğer izolasyonu??

TAV- zor havayolu riskini artıran faktörler

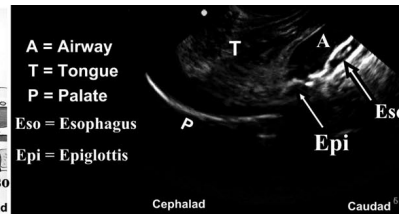
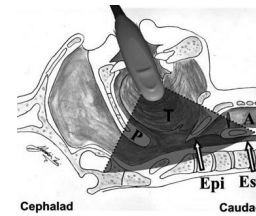
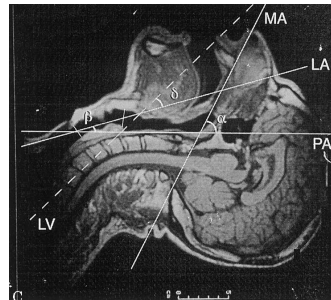
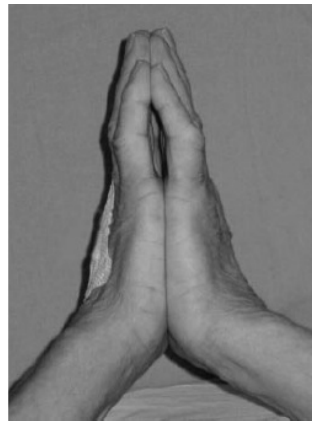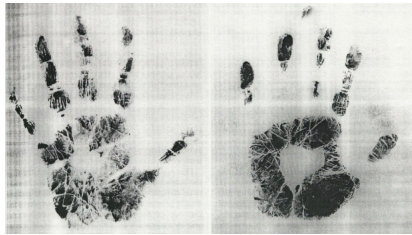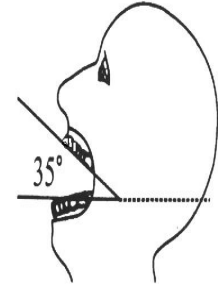
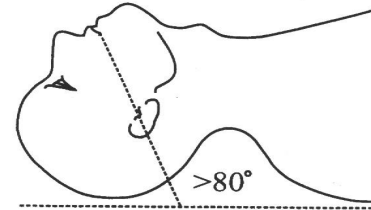
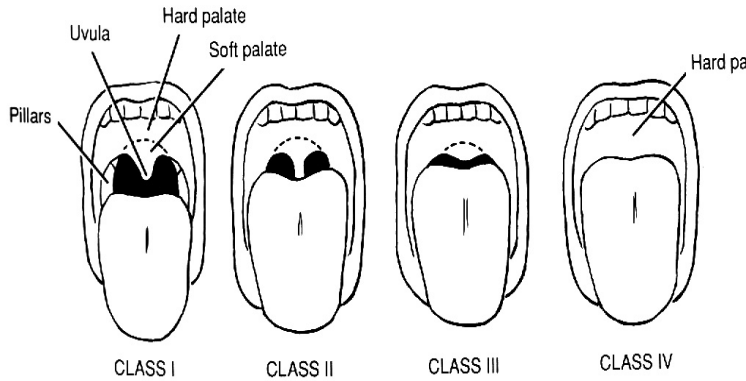
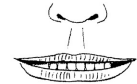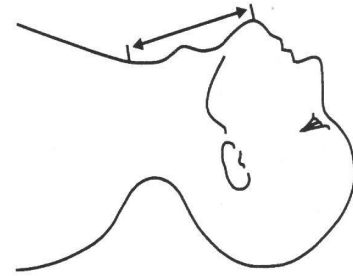
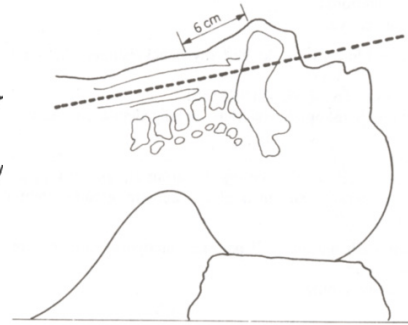
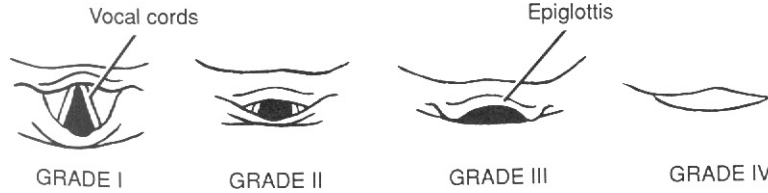
Upper airway

Short neck and increased neck circumference
Prominent upper incisors with a receding mandible
Limited cervical mobility
Limited jaw opening due to previous surgery
Radiation therapy of the neck
Hemiglossectomy/
hemimandibulectomy
Tumors (mouth, tongue, epiglottis)

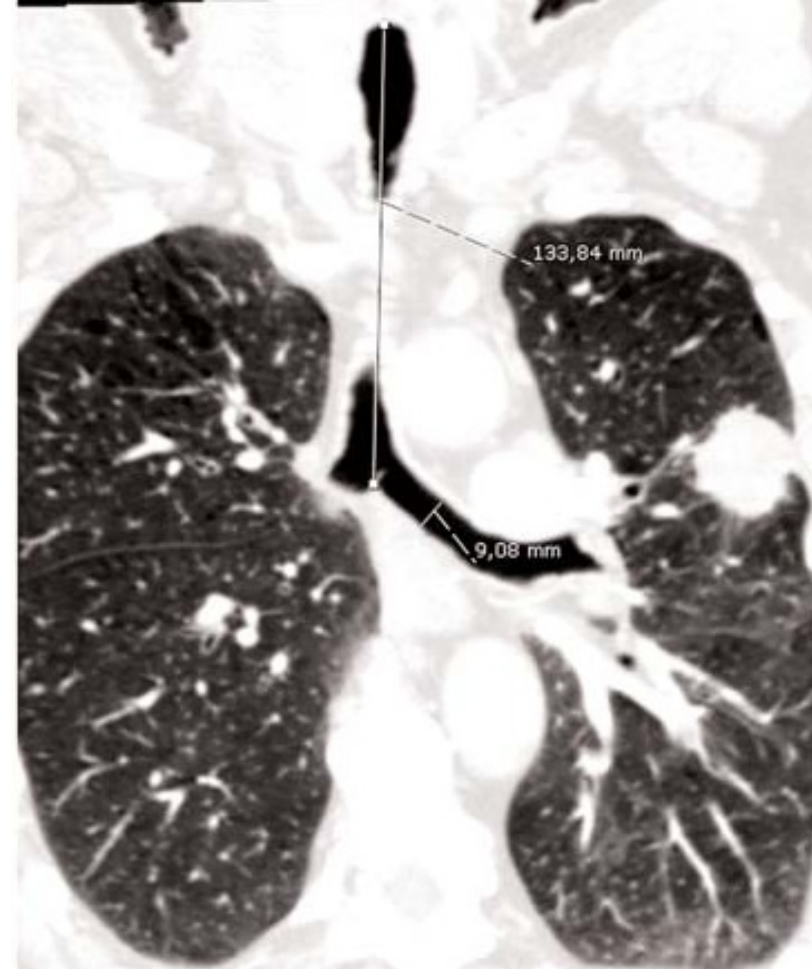
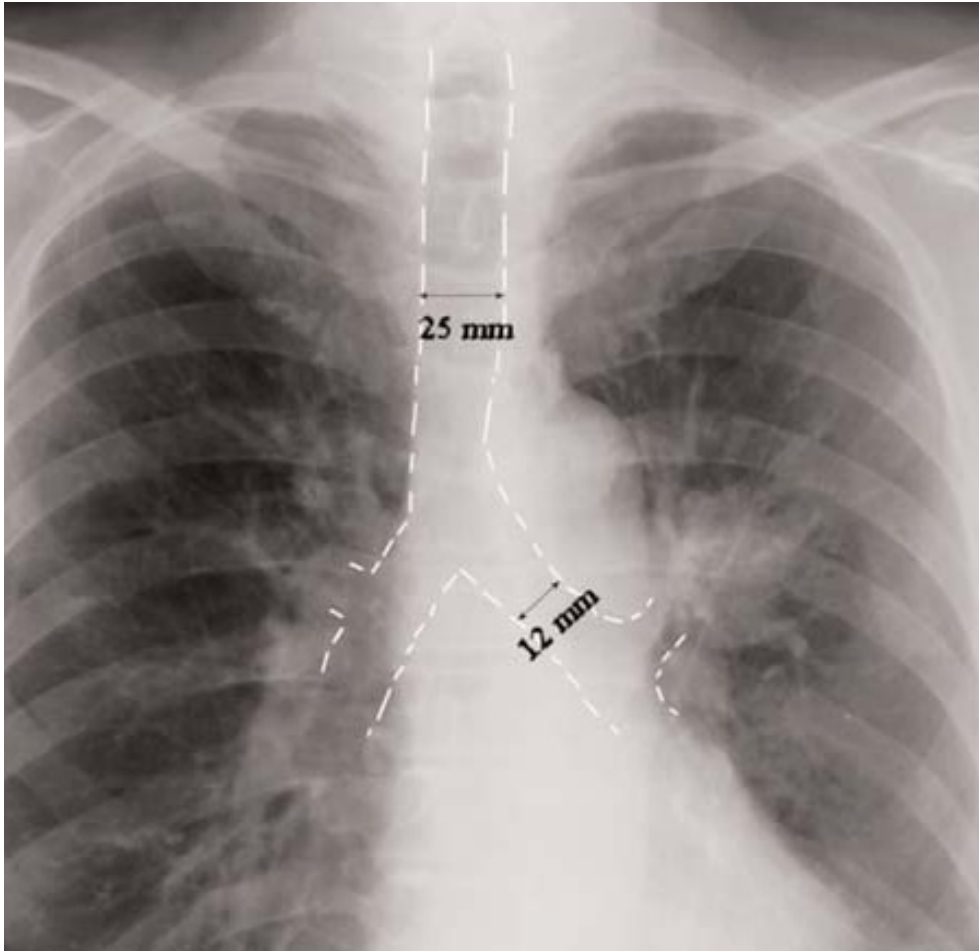
Lower airway

Existing tracheostomy in place
Distorted anatomy (trachea/bronchus)
Compression at the entrance of left mainstem bronchus

PREOPERATİF HAVAYOLU DEĞERLENDİRMESİ



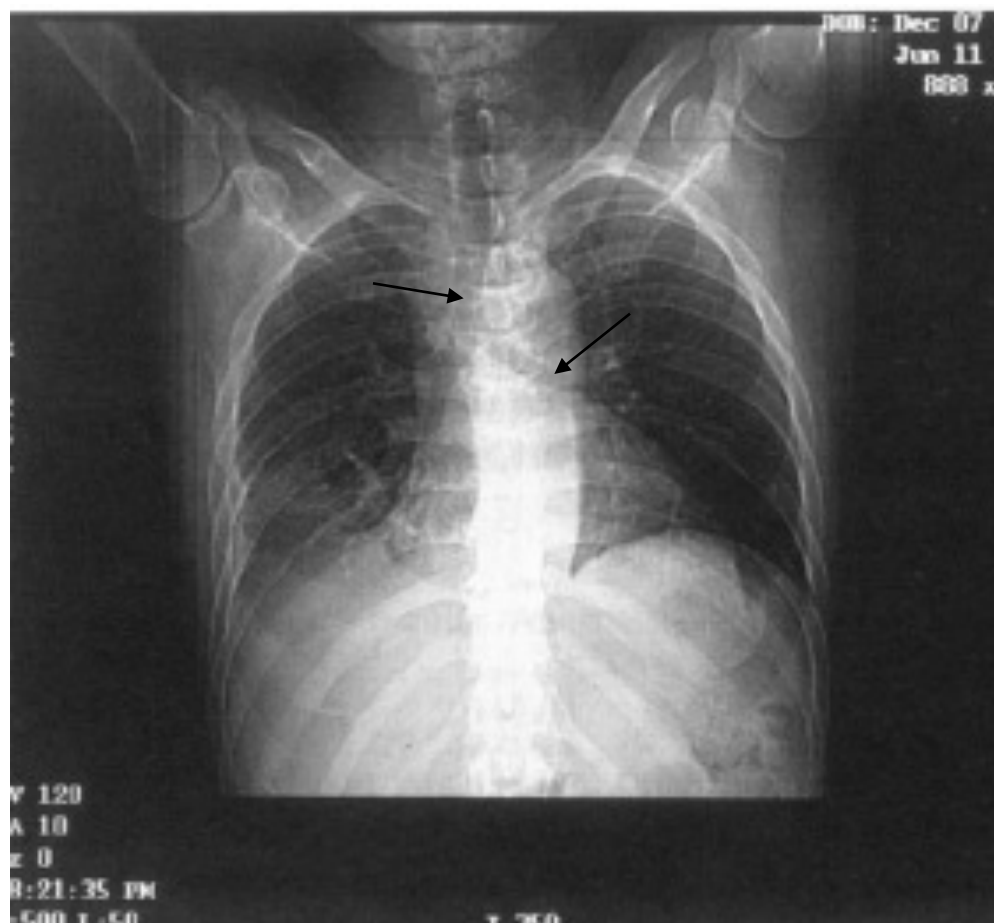Trakea ve Bronş Anatomisi



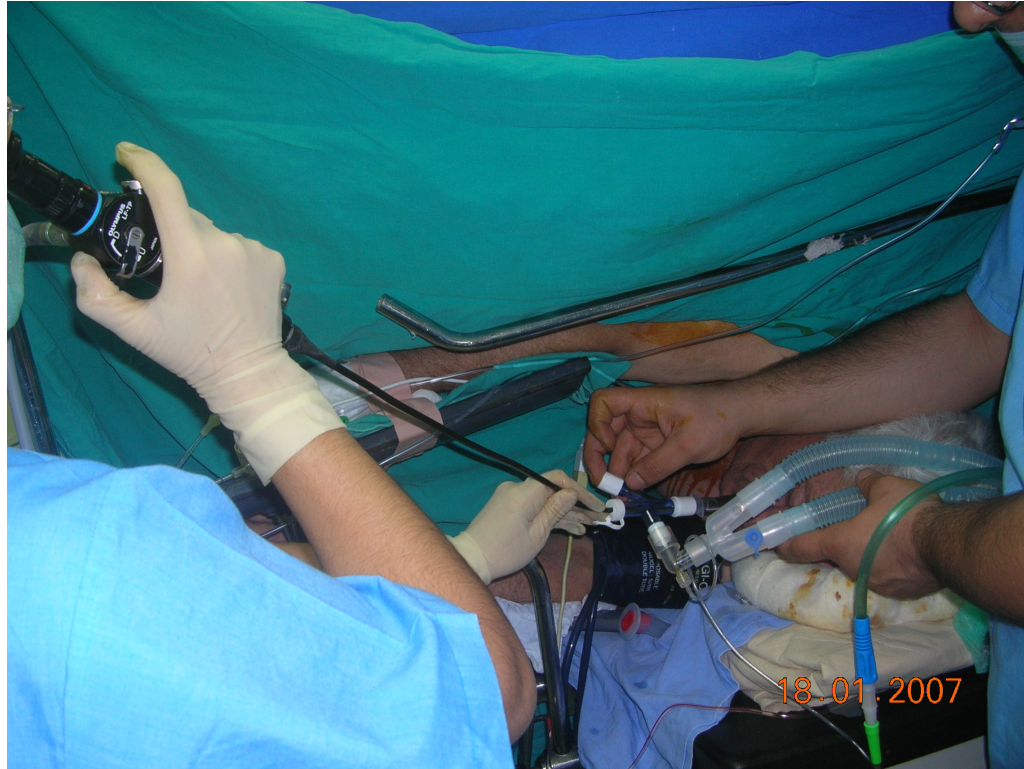
Unexpected Small Tracheobronchial Tree Size and Separation of the Lungs

Journal of Cardiothoracic and Vascular Anesthesia, Vol 16, No 2 (April), 2002: pp 260-266

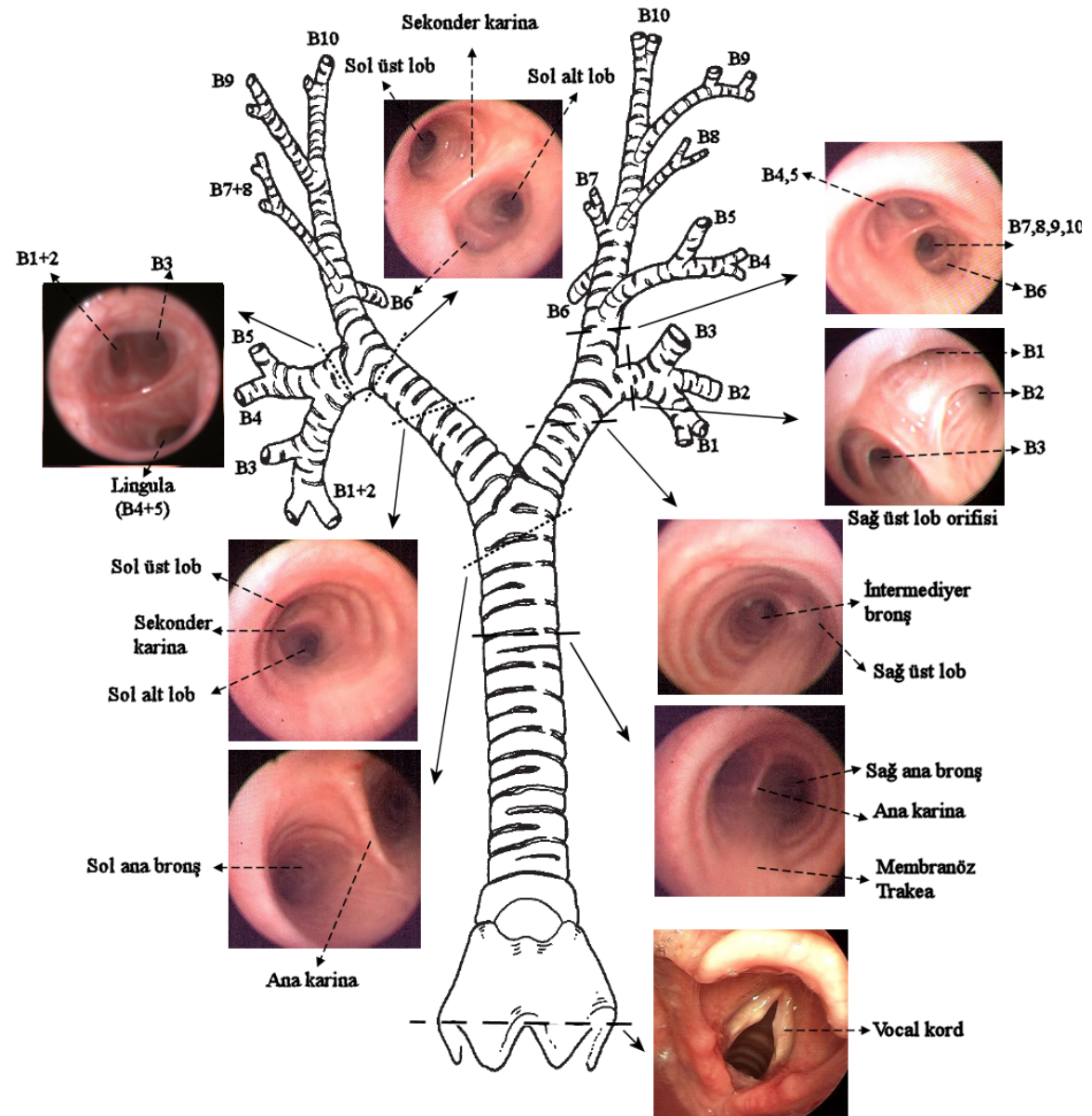
Vanna Soonthon-Brant, MD
Jonathan L. Benumof, MD
Department of Anesthesiology
University of California, San Diego
San Diego, CA



Fleksibl Fiberoptik Bronkoskopi



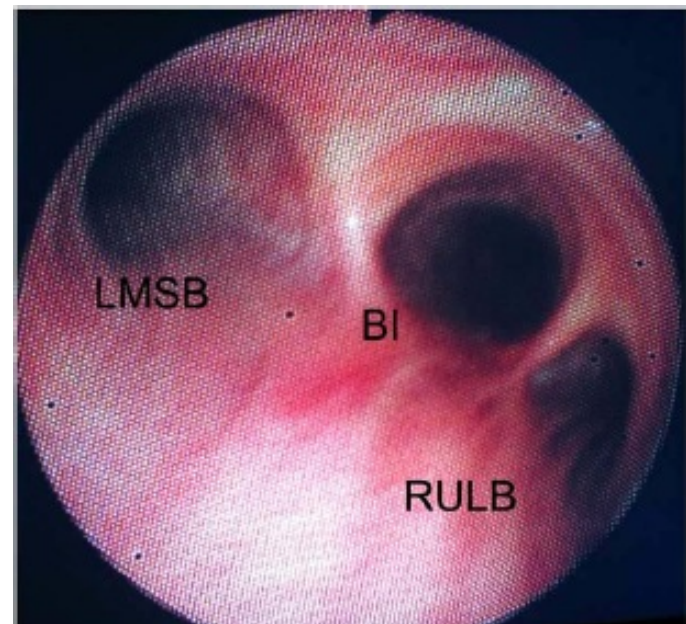
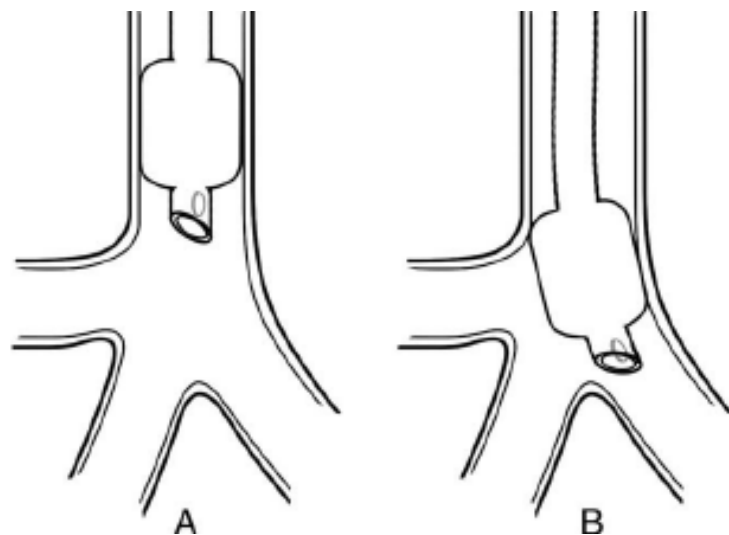
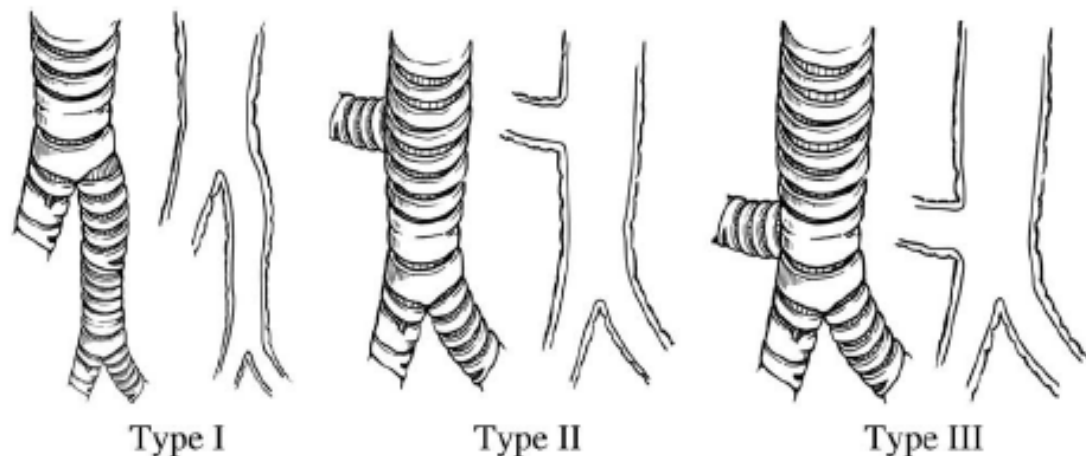
Fiberoptik Görüntülerin Tanınması



Inability to ventilate the lungs of a patient with tracheal anomaly and in prone position

Journal of Clinical Anesthesia (2008) 20, 386–388

Ramprasad Sripada MD, MMM, CPE (Associate Professor)^{a,*},
Kristal Keys MD (Resident)^a, Kurt M. Eichholz MD (Assistant Professor)^b

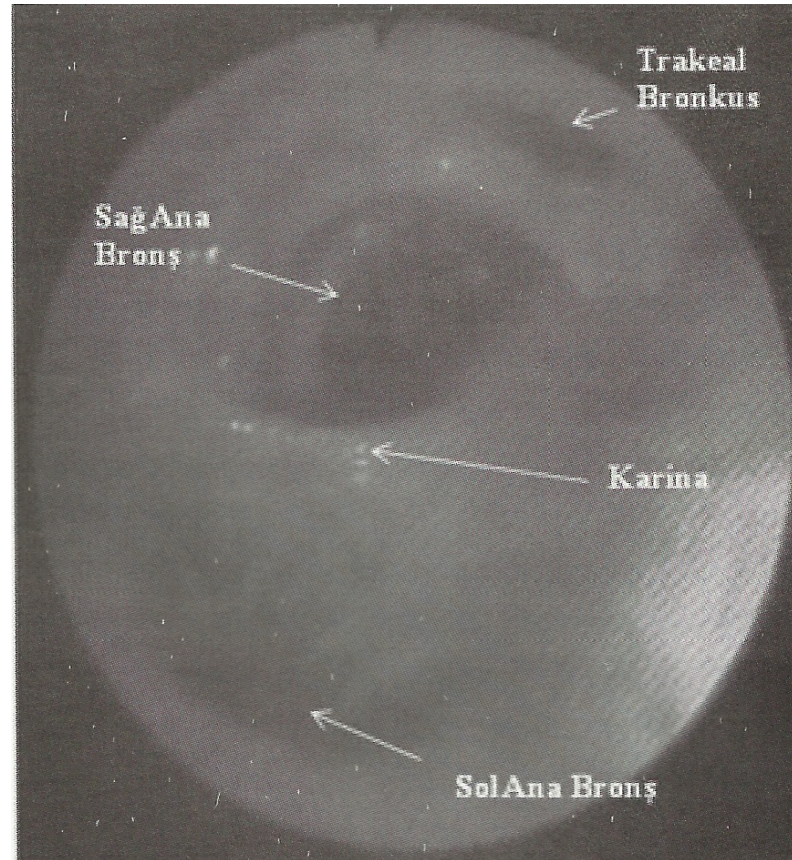


Olgu Sunumu

Konjenital Trakeal Bronkusta Sağ Akciğer İzolasyonu

Alparslan Kuş, Tülay Hoşten, Tülay Şahin, Salih Topçu*, Mine Solak, Kamil Tokar

Kocaeli Üniversitesi Tıp Fakültesi Anesteziyoloji ve Reanimasyon ve Göğüs Cerrahisi* Anabilim Dalları, Kocaeli



about us | articles | bronchial anatomy quiz | bronchoscopy simulator | contact us | restricted articles

ThoracicAnesthesia.com
Consultation, Information & Reference
University Faculty Network

Categories

- general
- Miscellaneous

Monthly

- March 2007

Pages

- About Us
- Articles
- Bronchial Anatomy Quiz
- bronchoscopy simulator
- Contact Us
- Restricted Articles

Links

- Anesthesia and Analgesia SCA

About Us

welcome to thoracic anesthesia.com

ThoracicAnesthesia.com is an Internet based education, information, and reference service for issues related to Anesthesia for Thoracic Surgery.

this service is a free not-for-profit continuing medical education activity which is offered to all practitioners of anesthesia and related areas of medicine and surgery. by clicking on the "bronchial anatomy quiz" tab readers can complete a needs assessment of their knowledge of tracheo-bronchial anatomy, which is fundamental to the skill of lung isolation for thoracic anesthesia. after completion of the Quiz, using the user name and password generated for the Quiz, readers have access at any time to the bronchoscopy simulator which is an interactive teaching simulation of fiberoptic bronchoscopy. Also, after completing the quiz, readers will have access to several review articles on lung isolation in the "restricted articles" section on the homepage.

there will be a regular update of articles recently published in the medical literature and a selection of REVIEW ARTICLES pertaining to Thoracic Anesthesia.

Readers are encouraged to submit clinical questions or cases in the "Contact Us" section which will then be discussed and answered by members of the International Editorial Board. As questions are answered they will be indexed and posted on the Web site along with the discussion and will form a library for future reference.

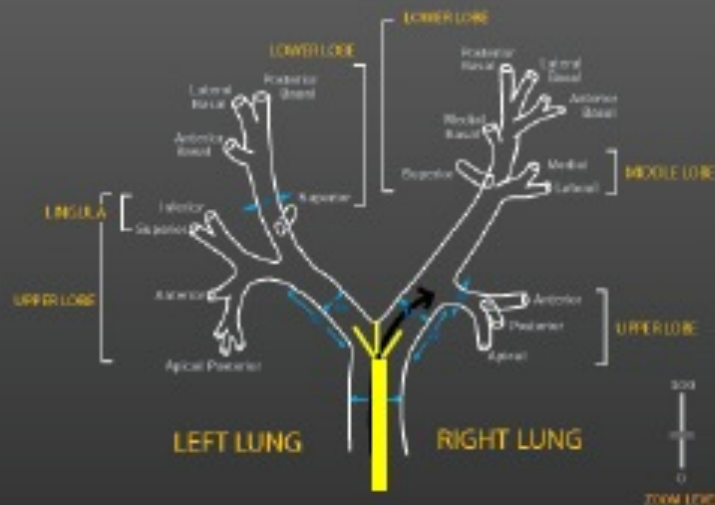
Authors and readers are encouraged to submit summaries or abstracts of relevant published information from other sources.

Simulator
Link

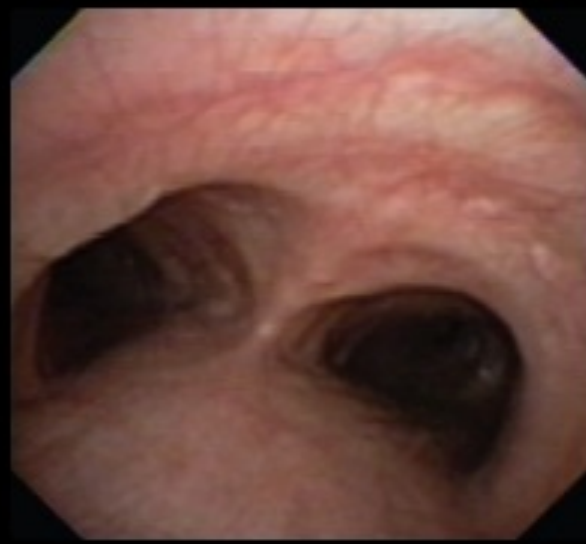


Thoracicanesthesia.com Bronchoscopy Simulation

BRONCHIAL TREE NAVIGATION MAP VIEW



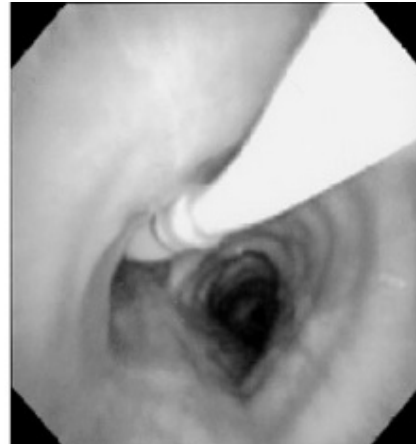
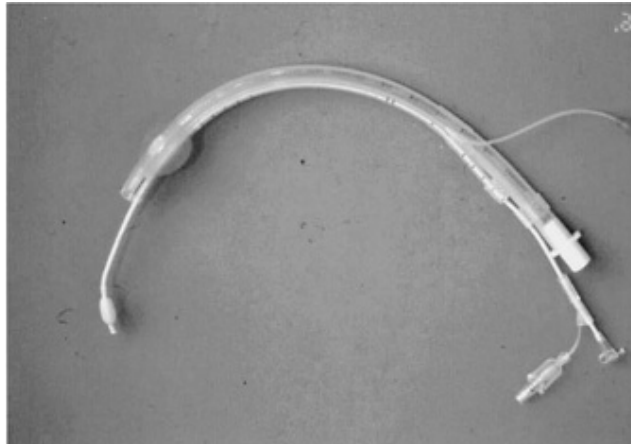
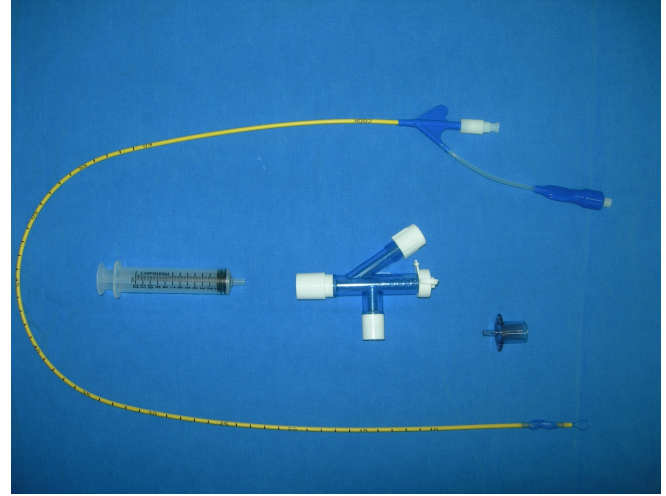

BRONCHOSCOPE VIEW



Navigation Map **Enabled** / Disabled
Navigation Labels **Enabled** / Disabled
Bronchoscope Labels **Enabled** / Disabled



Bronchoscope Navigation



OF ANESTHESIOLOGISTS
DIFFICULT AIRWAY ALGORITHM

1. Assess the likelihood and clinical impact of basic management problems:

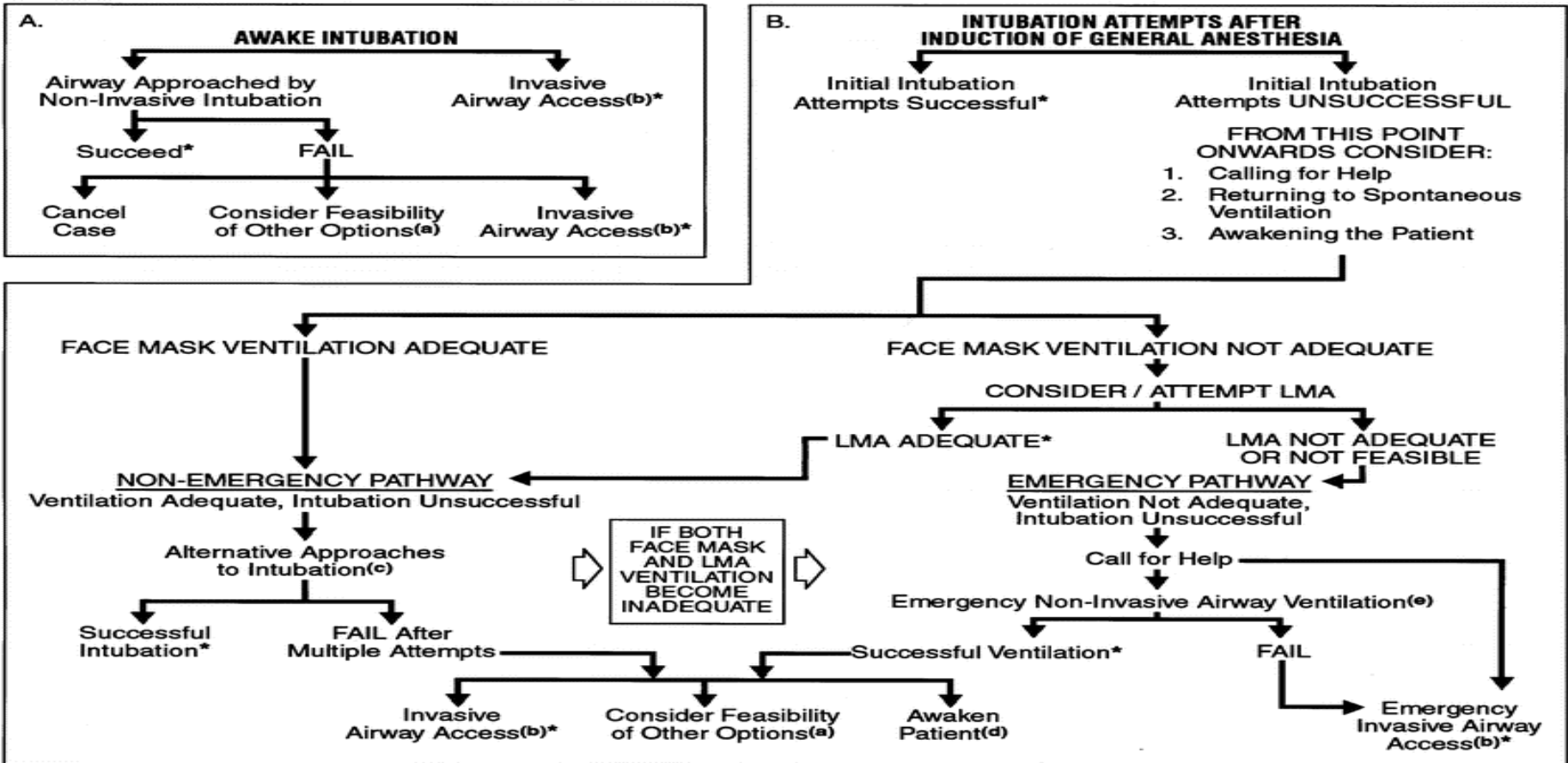
- A. Difficult Ventilation
- B. Difficult Intubation
- C. Difficulty with Patient Cooperation or Consent
- D. Difficult Tracheostomy

2. Actively pursue opportunities to deliver supplemental oxygen throughout the process of difficult airway management

3. Consider the relative merits and feasibility of basic management choices:

- A. Awake Intubation vs. Intubation Attempts After Induction of General Anesthesia
- B. Non-Invasive Technique for Initial Approach to Intubation vs. Invasive Technique for Initial Approach to Intubation
- C. Preservation of Spontaneous Ventilation vs. Ablation of Spontaneous Ventilation

4. Develop primary and alternative strategies:



* Confirm ventilation, tracheal intubation, or LMA placement with exhaled CO₂

One-Lung Ventilation in Patients With Difficult Airways

Satoshi Hagihira, MD, PhD, Masaki Takashina, MD, Takahiko Mori, MD, and Ikuto Yoshiya, MD, PhD

Journal of Cardiothoracic and Vascular Anesthesia, Vol 12, No 2 (April), 1998: pp 186-188

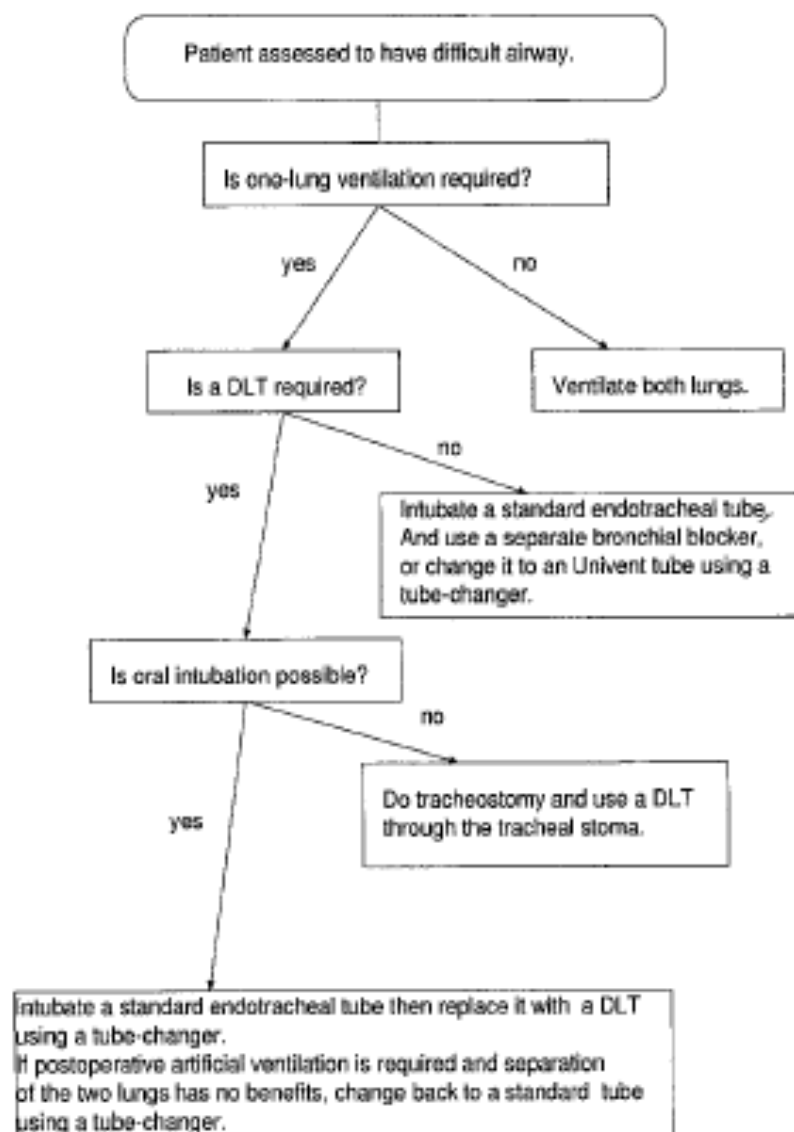
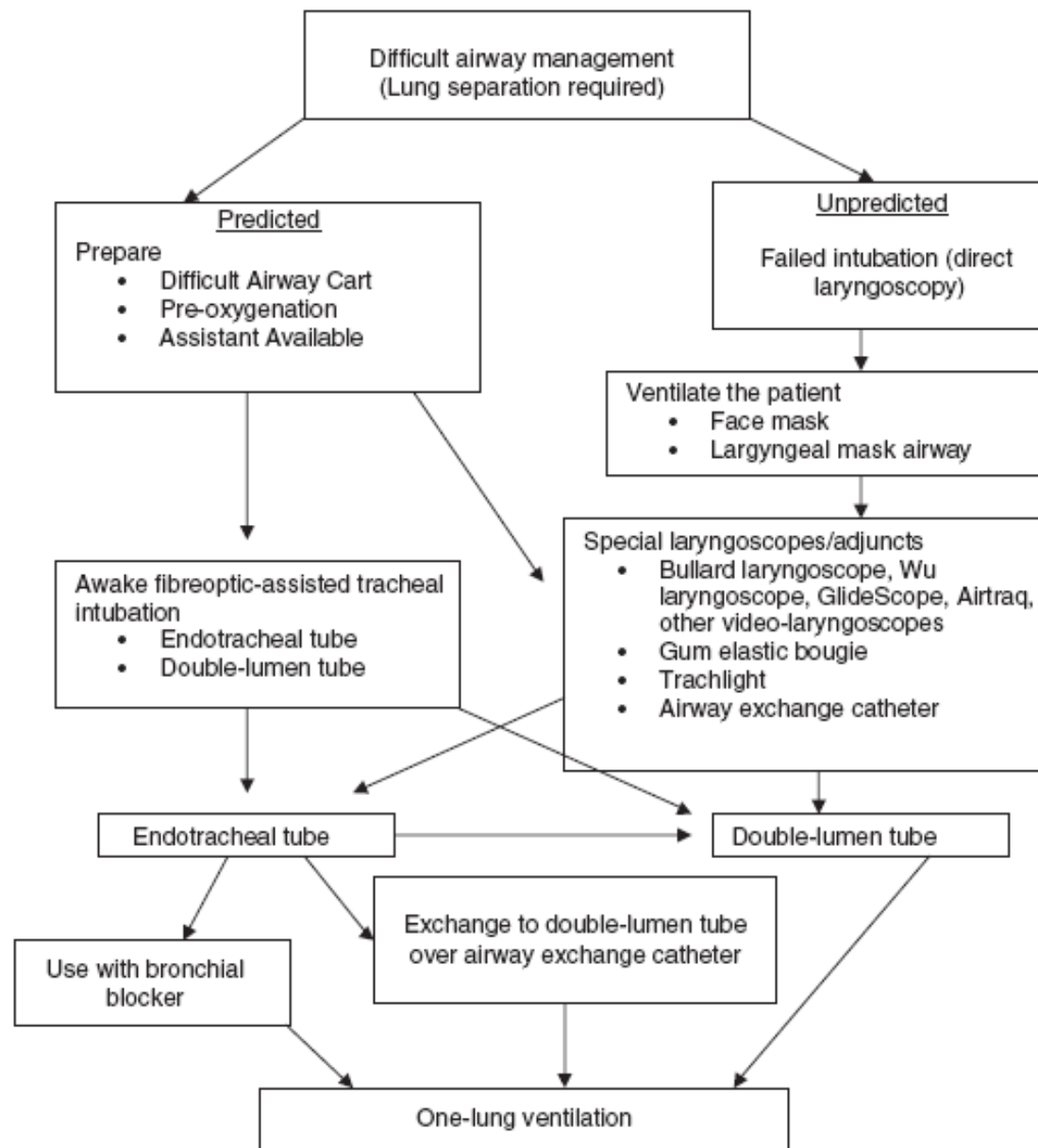


Fig 1. One-lung ventilation strategies for patients with difficult airways.

Algorithm for difficult airway management when lung separation is required.



Lung separation and the difficult airway

Special laryngoscopes/adjuncts

- Bullard laryngoscope, Wu laryngoscope, GlideScope, Airtraq, other video-laryngoscopes
- Gum elastic bougie
- Trachlight
- Airway exchange catheter

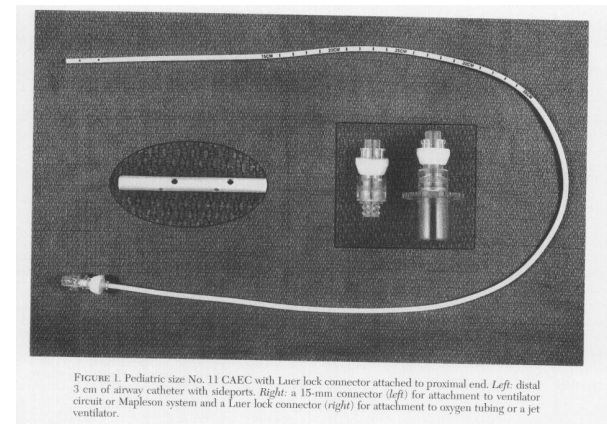
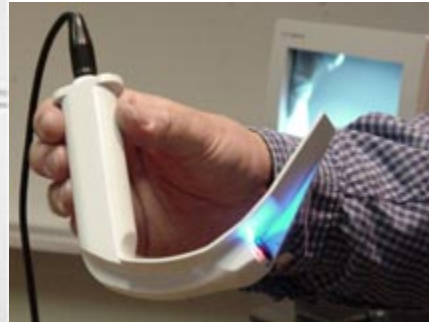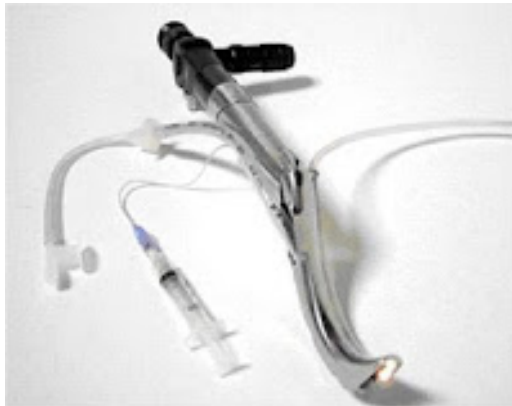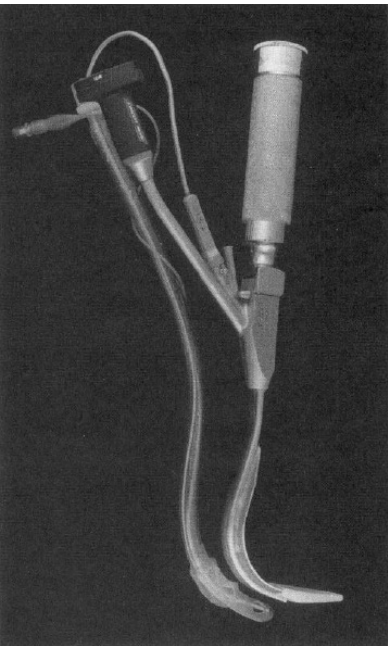


FIGURE 1. Pediatric size No. 11 CAEC with Luer lock connector attached to proximal end. *Left:* distal 3 cm of airway catheter with sideports. *Right:* a 15-mm connector (*left*) for attachment to ventilator circuit or Mapleson system and a Luer lock connector (*right*) for attachment to oxygen tubing or a jet ventilator.

Lung isolation techniques for patients with difficult airway

Javier H. Campos

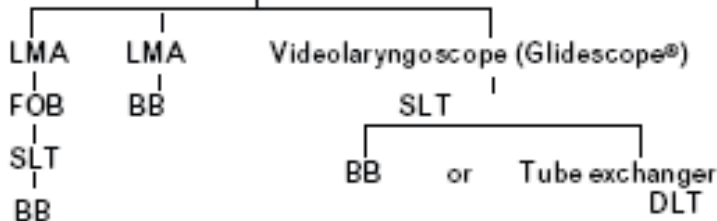
Current Opinion in Anaesthesiology

2010, 23:12–17

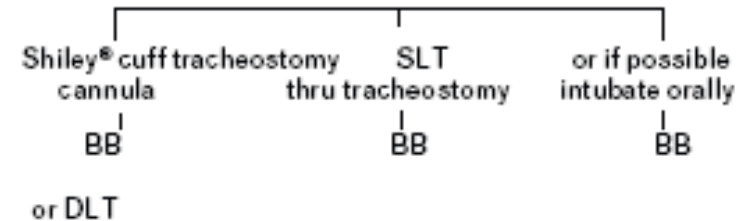
Lung isolation and difficult airway

Difficult intubation after induction

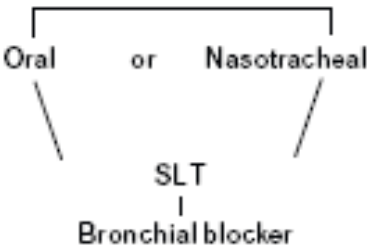
Secure airway



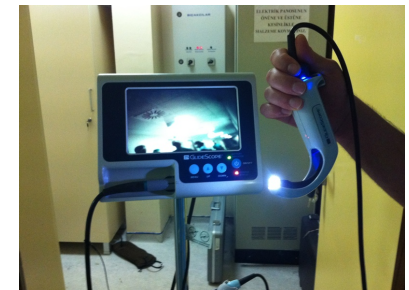Tracheostomy in place



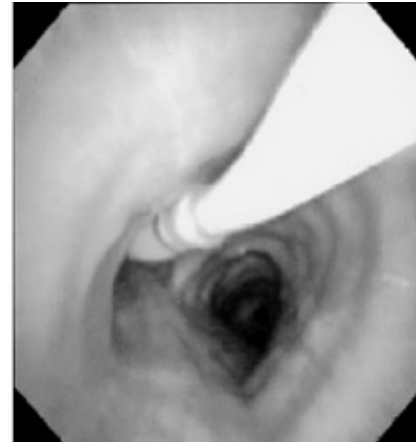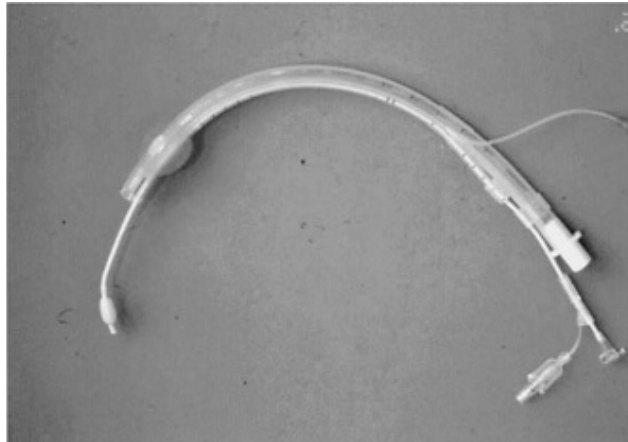
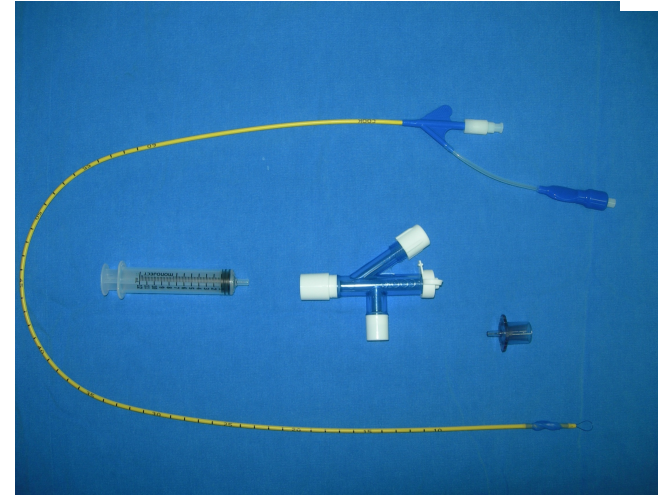

Awake intubation



- Arndt® blocker
- Cohen® blocker
- Fuji® uniblocker



Çift Lümenli Tüp? Bronşiyal Bloker?



Pro: The New Bronchial Blockers Are Preferable to Double-Lumen Tubes for Lung Isolation

Edmond Cohen, MD

Journal of Cardiothoracic and Vascular Anesthesia, Vol 22, No 6 (December), 2008; pp 920-924

Table 1. Indications for the Use of Endobronchial Blockers

Lung isolation versus lung separation

Video-assisted thoracoscopy; increase the number of patients who required OLV

Avoid the need for tube exchange

The difficult airway

Patients with a difficult airway (Mallampati 3 or 4)

Patients postlaryngeal/pharyngeal surgery

Patients with tracheotomy

Patients with distorted bronchial anatomy from aneurysm compression or intraluminal tumor

Patients who require nasotracheal intubation

Patients with immobility or kyphoscoliosis

Patients with head and neck trauma

Surgical procedure not involving the lung

Esophageal surgery

Spine surgery that required transthoracic approach

Minimally invasive cardiac surgery

Management

VAT procedures in which a wedge resection or chest exploration is planned

Possible segmental blockade in patients intolerant to OLV

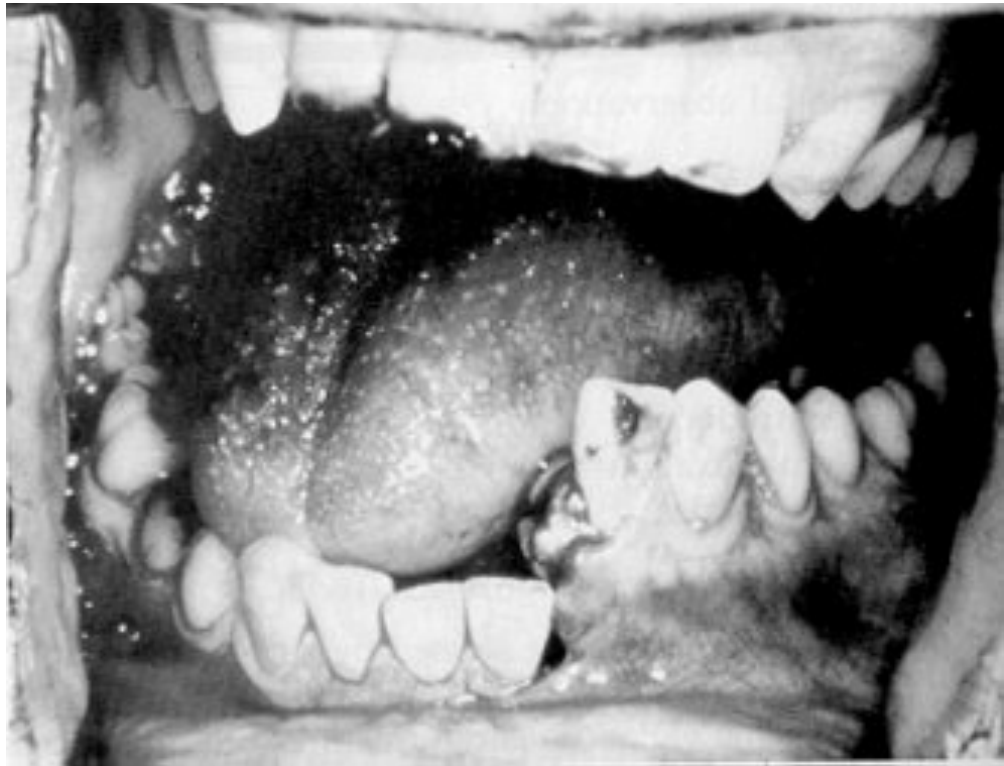Morbidly obese patients

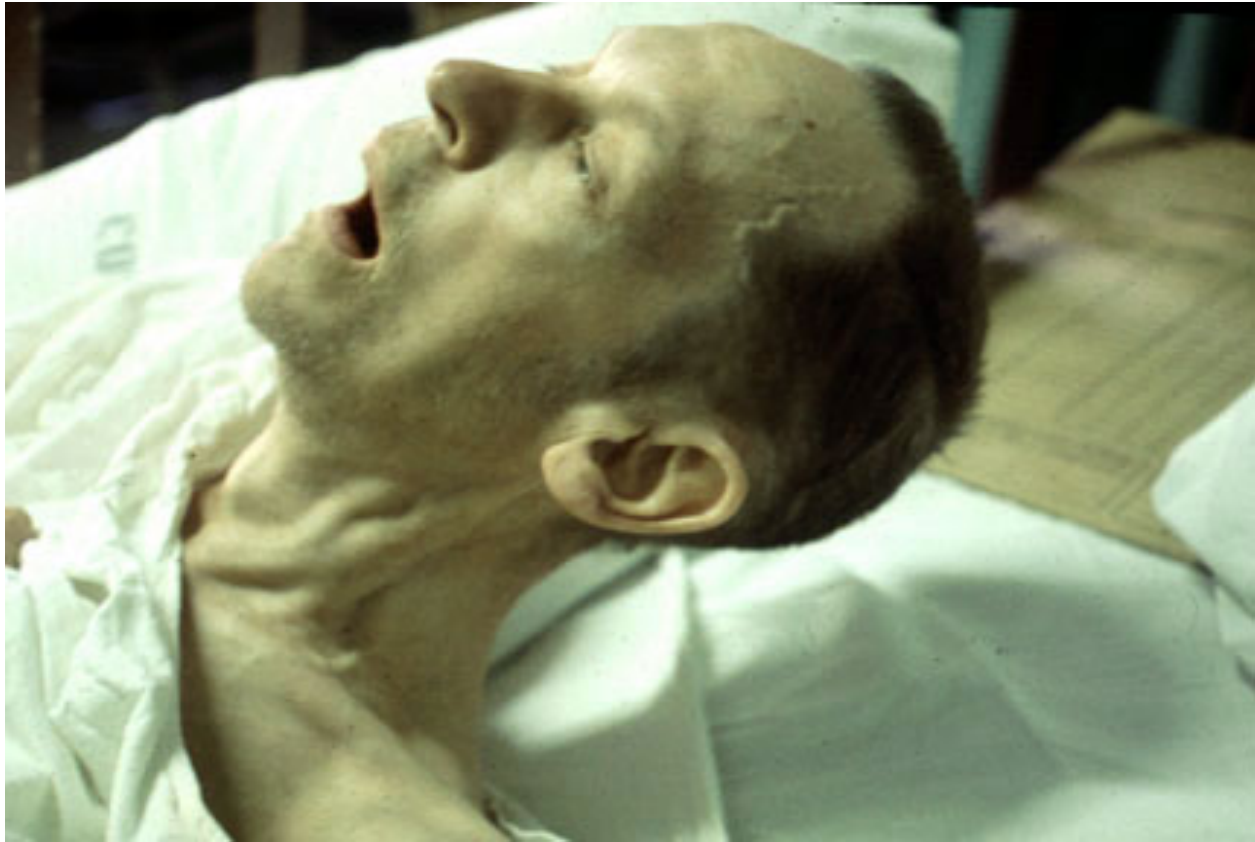Small-size adult or pediatrics

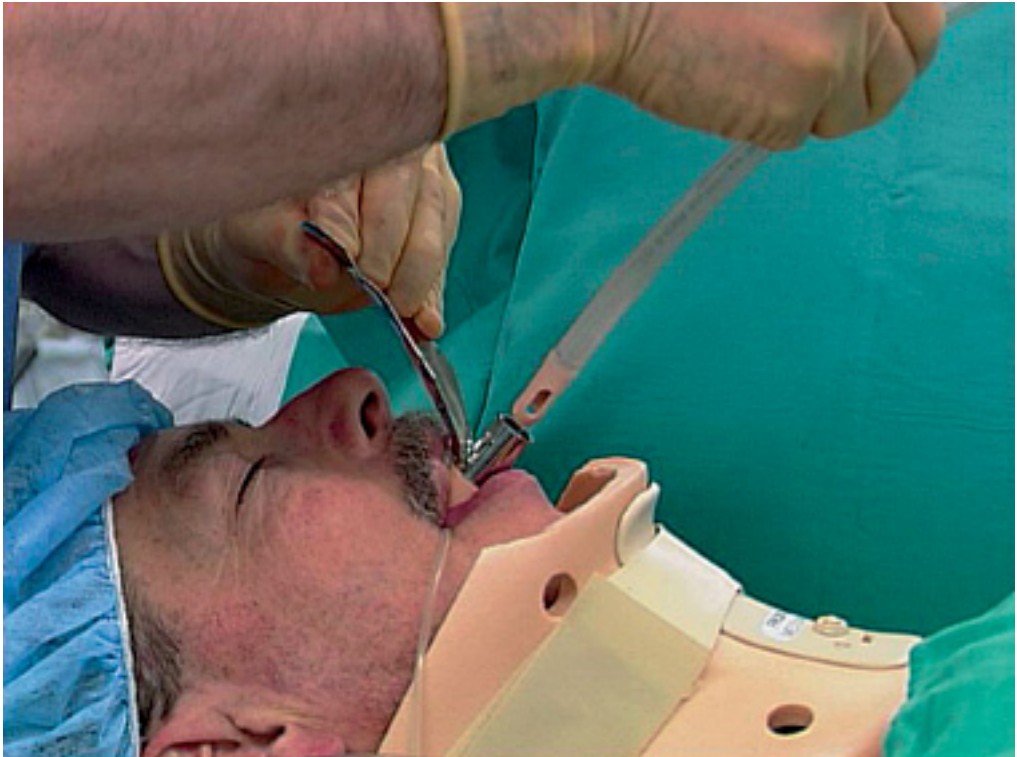Patients who require intraoperative lung isolation

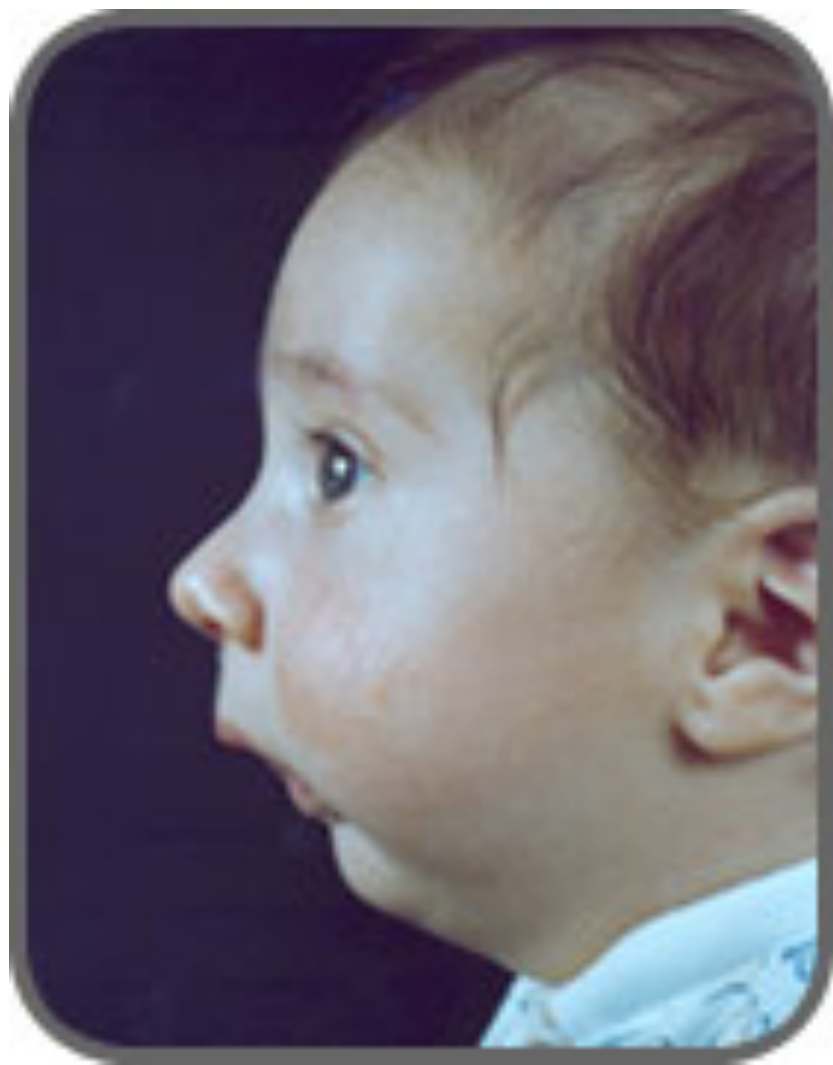Patients who arrive intubated to the operating room from the intensive care unit

The need to teach the new generation and for practice for the present generation









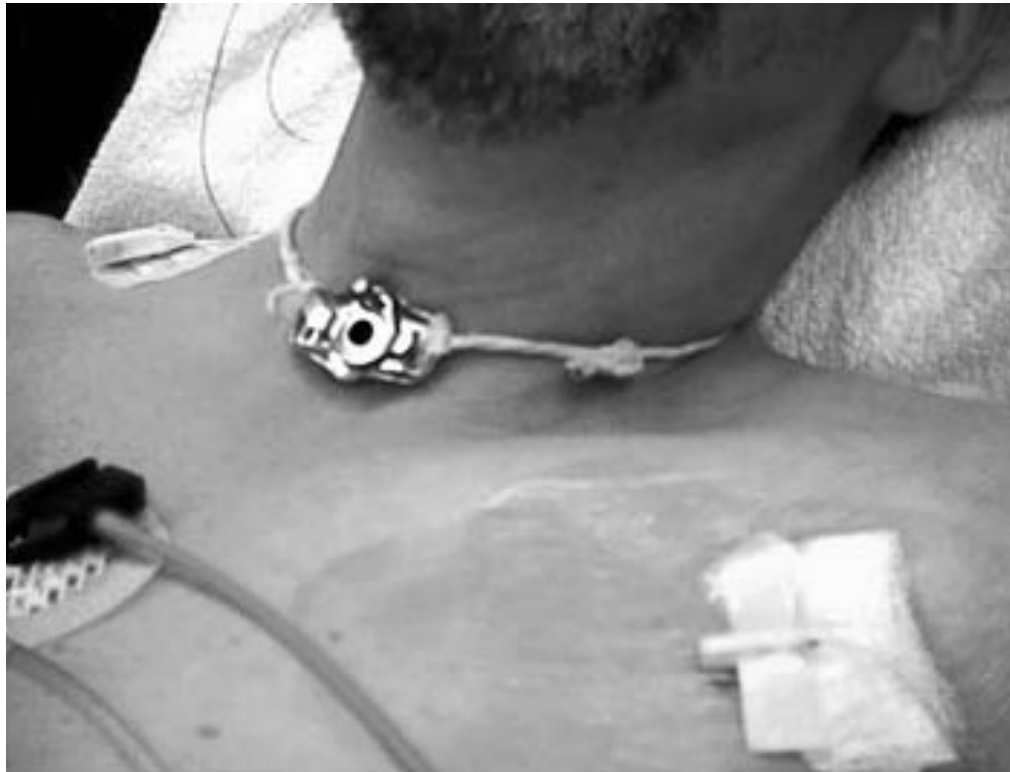The Gorham-Stout syndrome: one lung ventilation with a bronchial blocker. A case of Gorham's disease with chylothorax

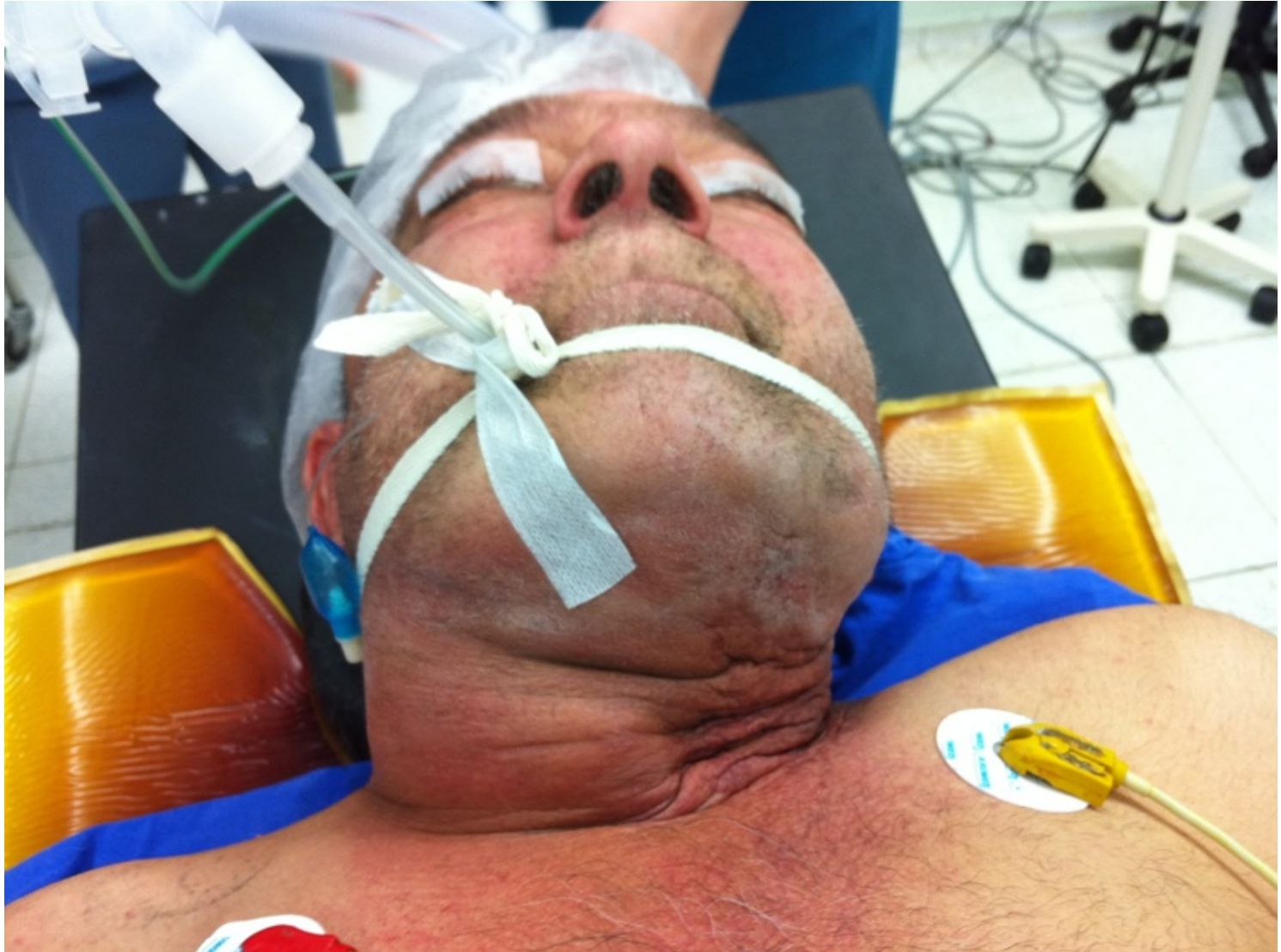2009 Blackwell Publishing Ltd, *Pediatric Anesthesia*, 19, 168–196

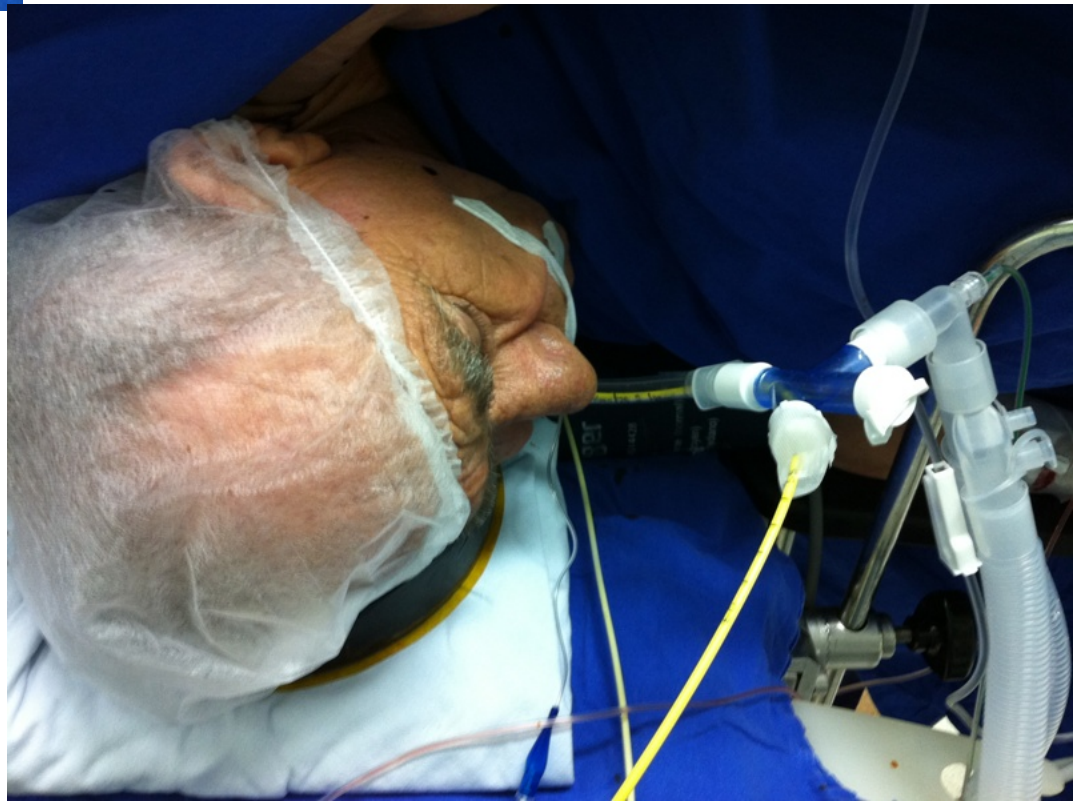
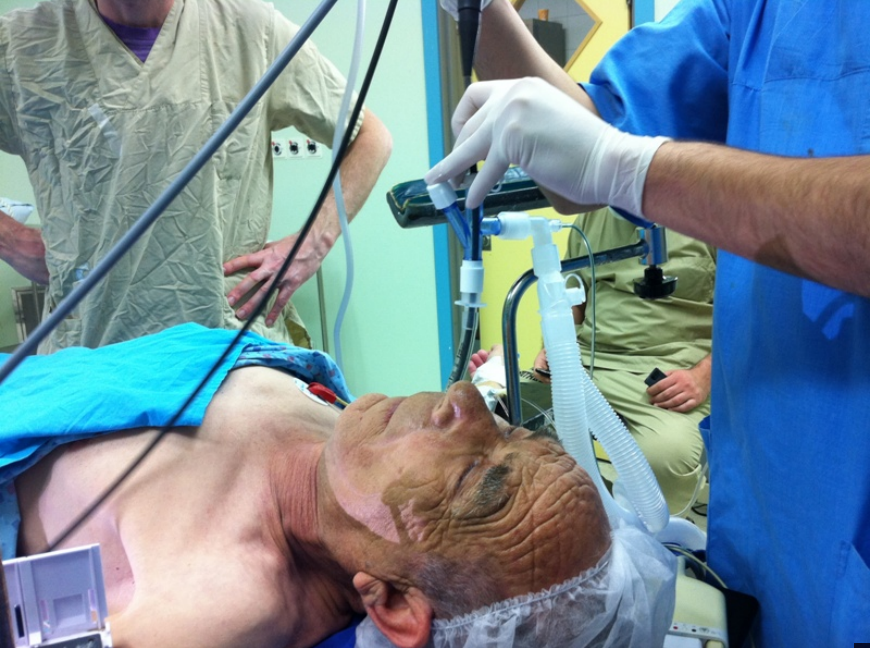TULAY SAHIN YILDIZ
ALPARSLAN KUS
MINE SOLAK
KAMIL TOKER

*Medical Faculty, Department of Anesthesiology, University of
Kocaeli, Kocaeli, Turkey*

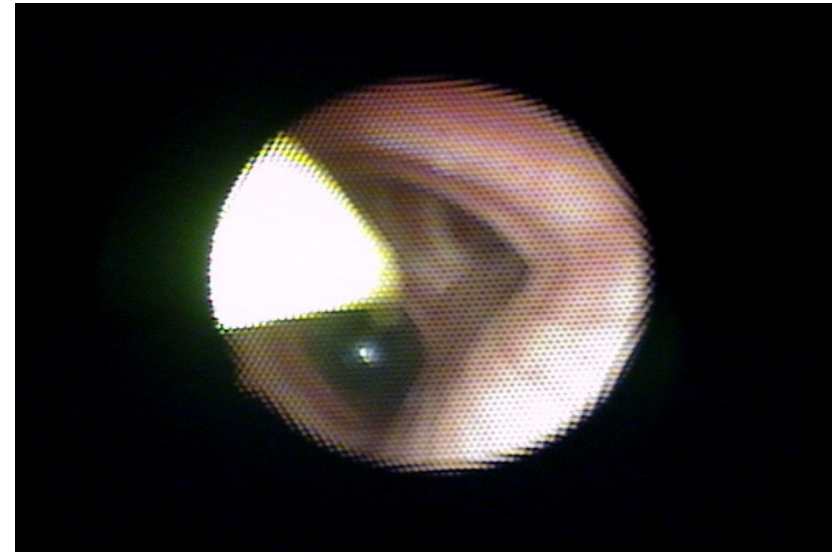
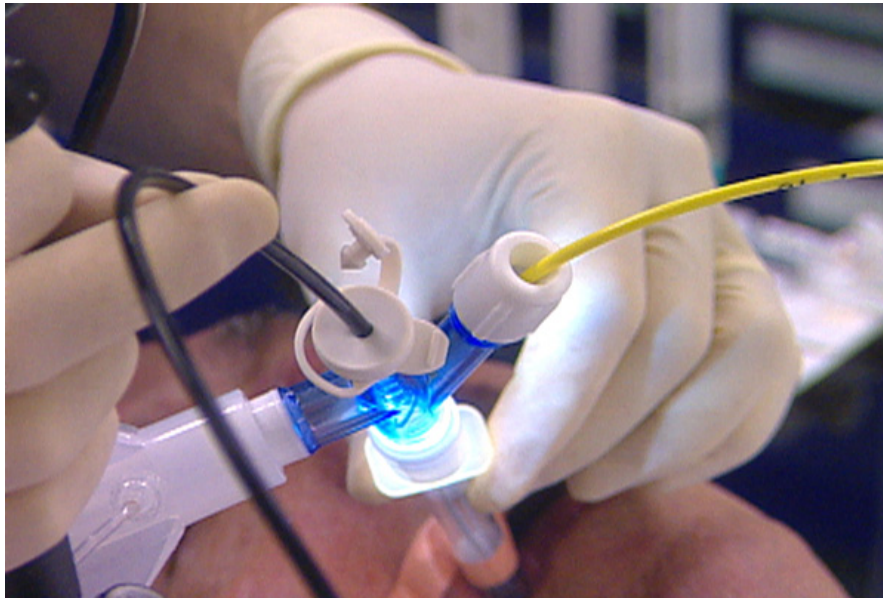
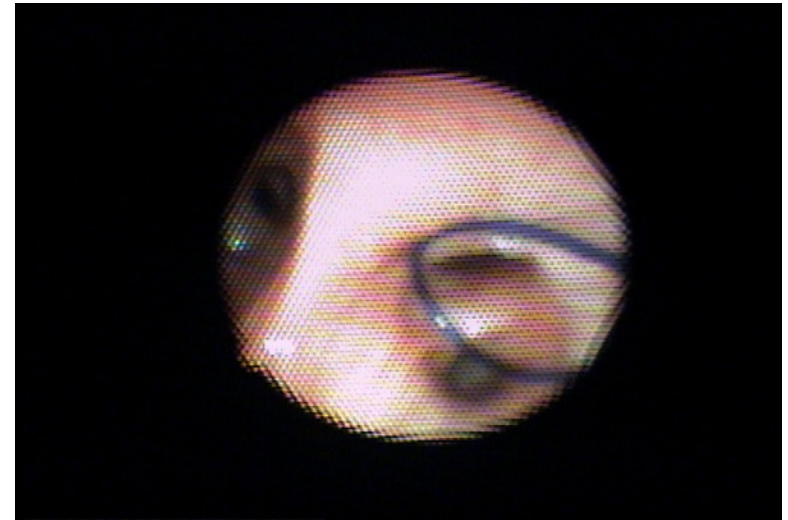
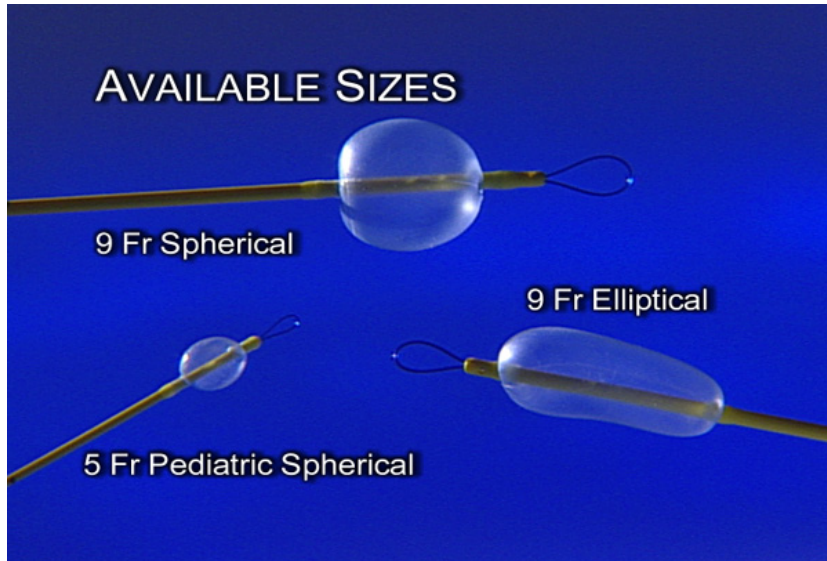
- 6 y erkek, bilateral şilotoraks, torasik kanal ligasyonu, TAV
- ETT (#5.5) ve FOB ile 5 Fr Arndt bronşiyal bloker







Bronşiyal blokerler

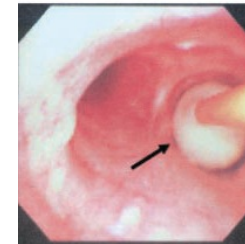
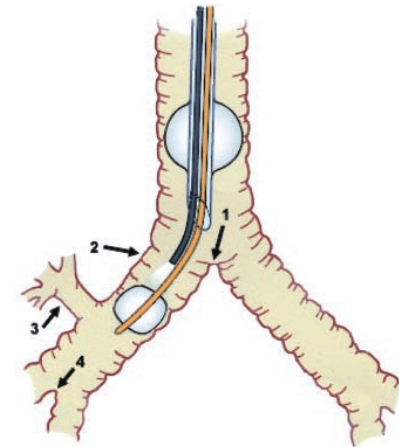
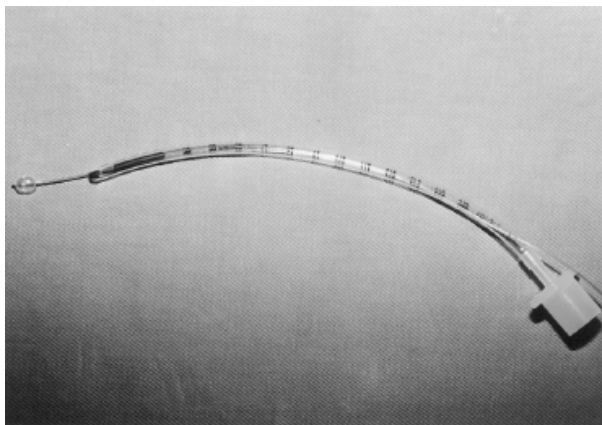



An Update on Bronchial Blockers During Lung Separation Techniques in Adults

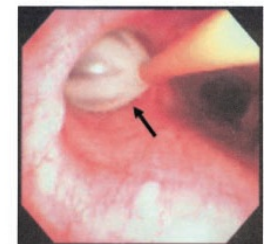
Javier H. Campos, MD

Anesth Analg 2003;97:1266-74

8 Fr. Fogarty Venous Embolectomy Catheter, 10 cc balloon



A

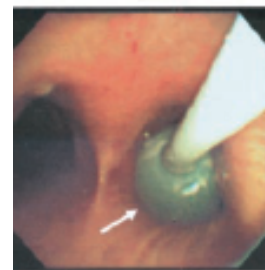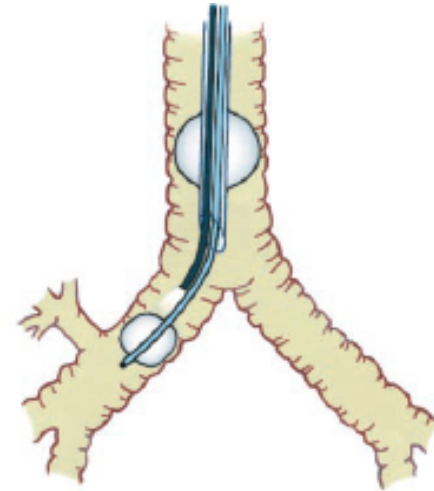
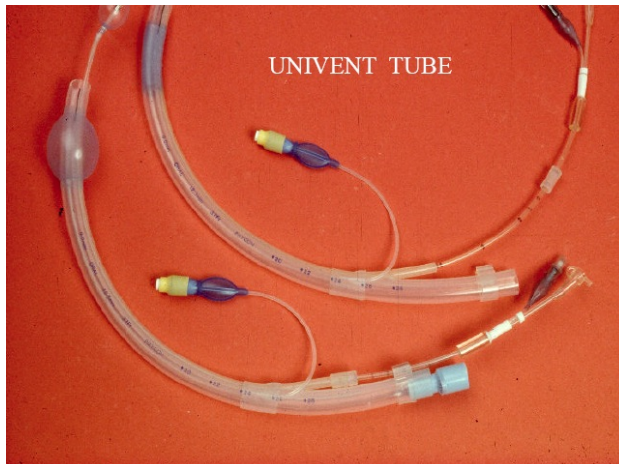


B

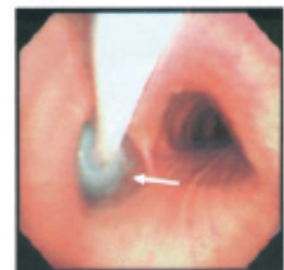
An Update on Bronchial Blockers During Lung Separation Techniques in Adults

Javier H. Campos, MD

Anesth Analg 2003;97:1266-74

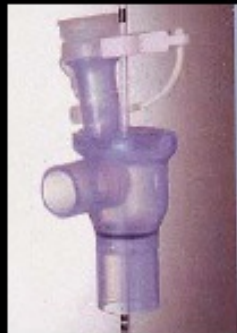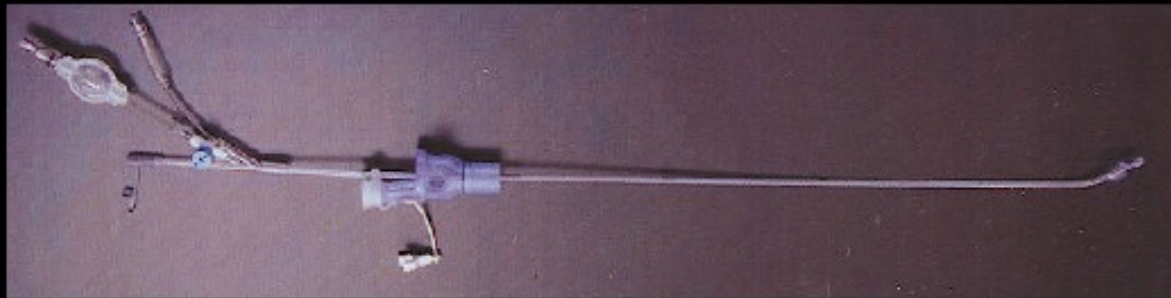


A



B

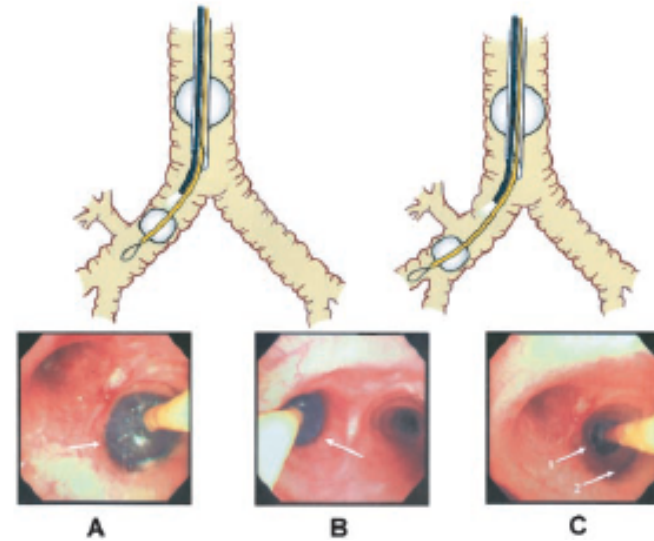
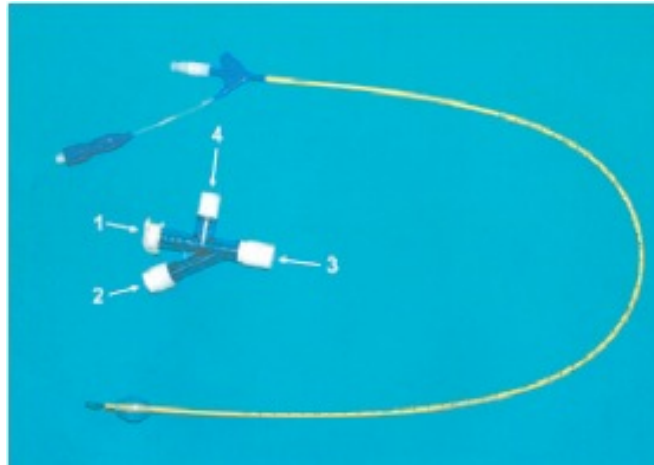
Fuji "Uni-Blocker"

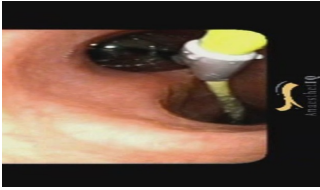

An Update on Bronchial Blockers During Lung Separation Techniques in Adults

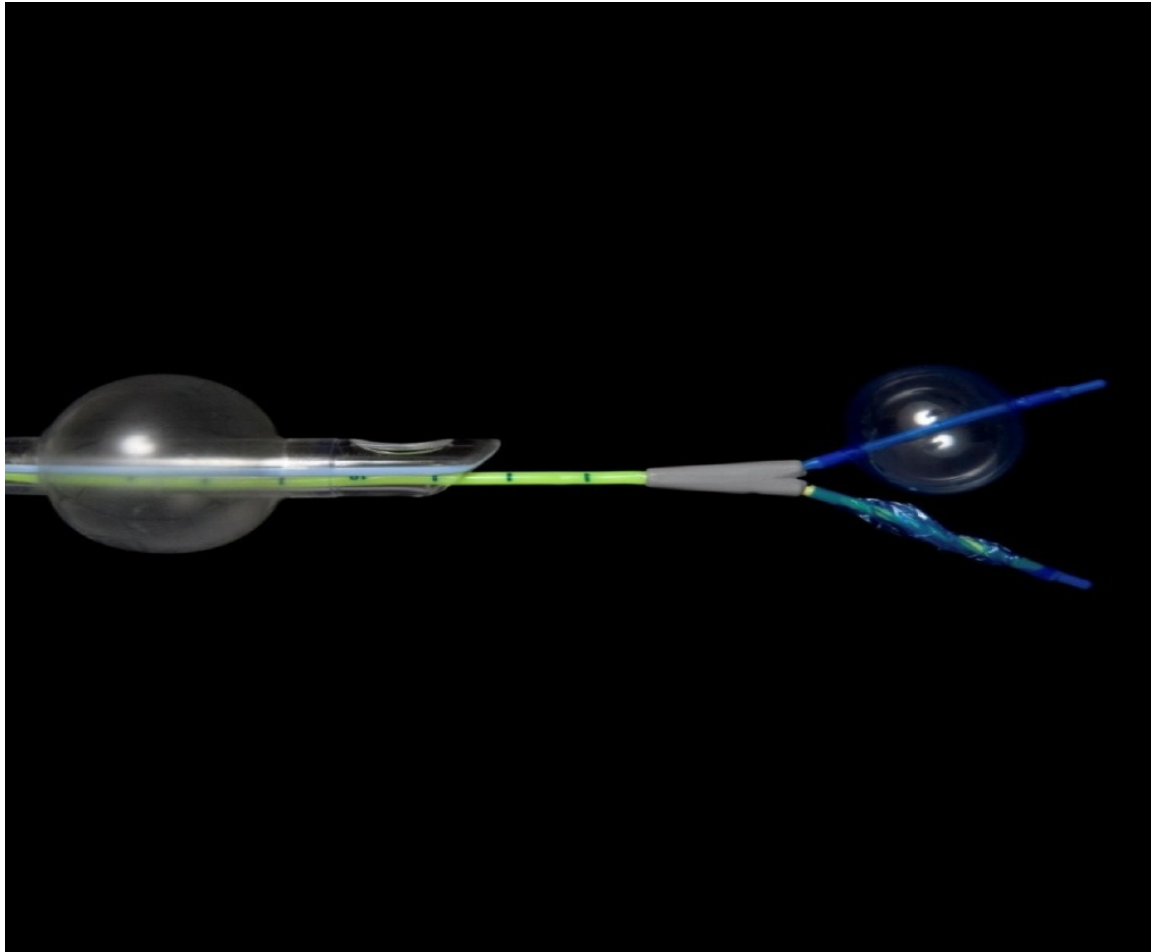
Javier H. Campos, MD

Anesth Analg 2003;97:1266-74

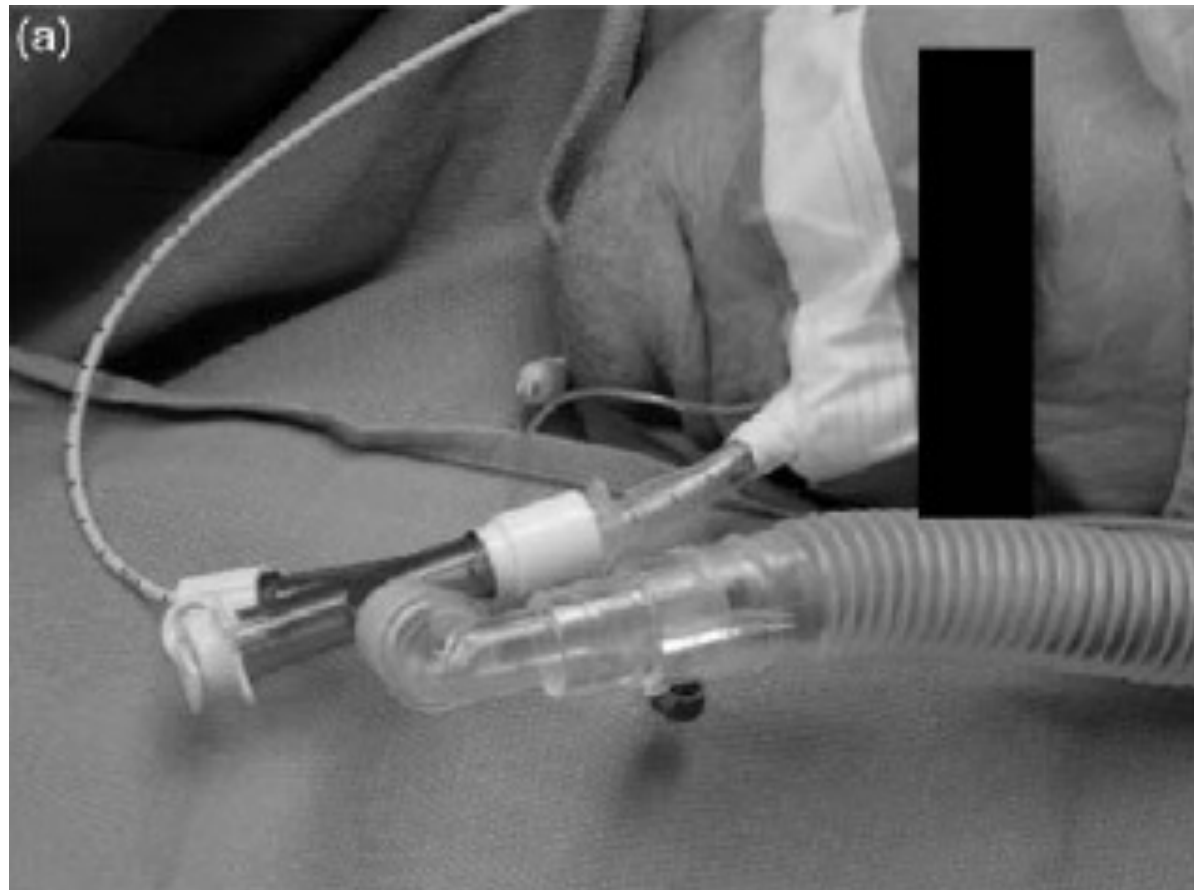




EZ-Bloker



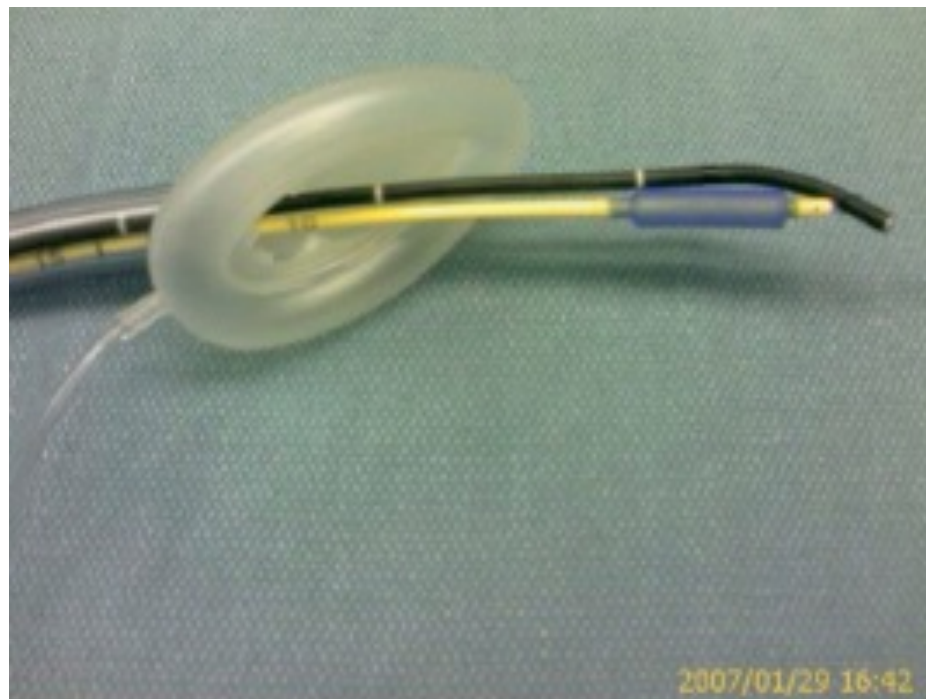Özellikler	Cohen	Arndt	Univent
Büyükük	9 Fr	5 Fr, 7 Fr ve 9 Fr	5 Fr, 9 Fr
Balon şekli	Yuvarlak	Yuvarlak veya oval	Yuvarlak
Yol gösterici mekanizma	Yönlendirici mekanizma baş tarafta	Fiberoptik bronkoskobu çevreleyen naylon kement kılavuz	Yok, tüpün sonunda
Önerilen en küçük ETT boyutu	9 Fr (8.0 ETT)	5 Fr (4.5 ETT), 7 Fr (7.0 ETT), 9 Fr (8.0 ETT)	9 Fr (8.0 ETT)
Murphy gözü	Var	9 Fr'de var	Yok
Merkezi kanal	İç çap 1.6 mm	İç çap 1.4 mm	İç çap 2.0 mm



Lung Isolation Using a Laryngeal Mask Airway and a Bronchial Blocker in a Patient With a Recent Tracheostomy

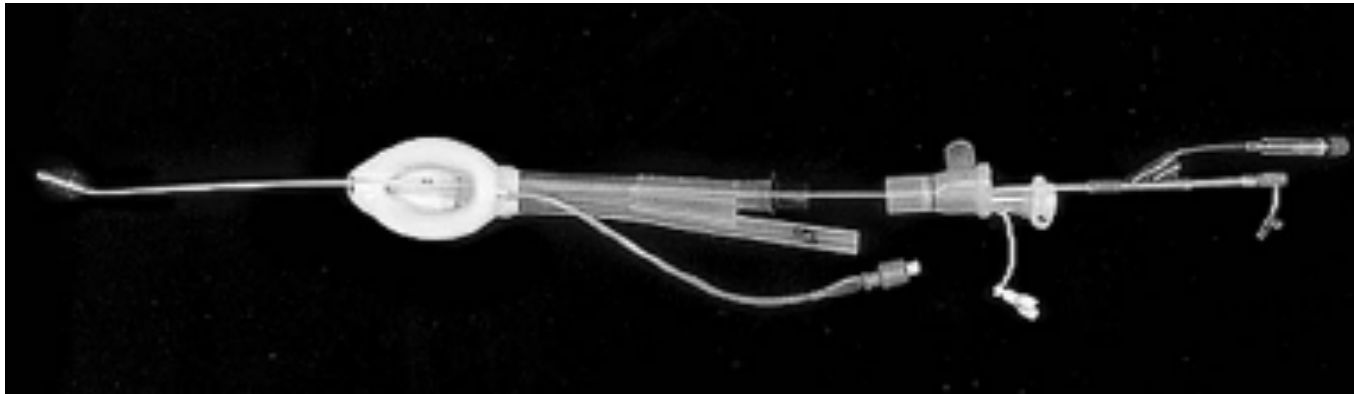
Albert R. Robinson III, MD,* Nikolaus Gravenstein, MD,*† Estibaliz Alomar-Melero, MD,*
and Yong G. Peng, MD*‡

Journal of Cardiothoracic and Vascular Anesthesia, Vol 22, No 6 (December), 2008: pp 883-886



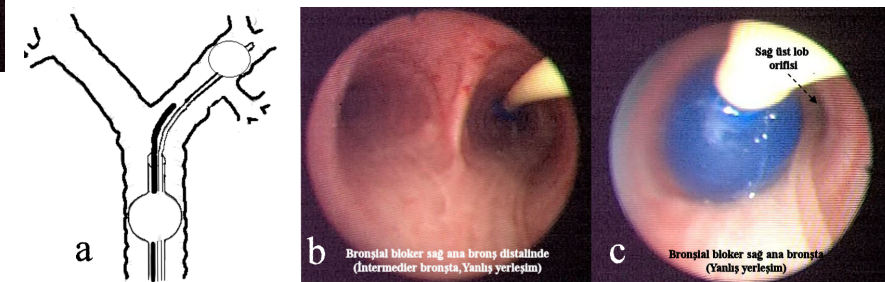
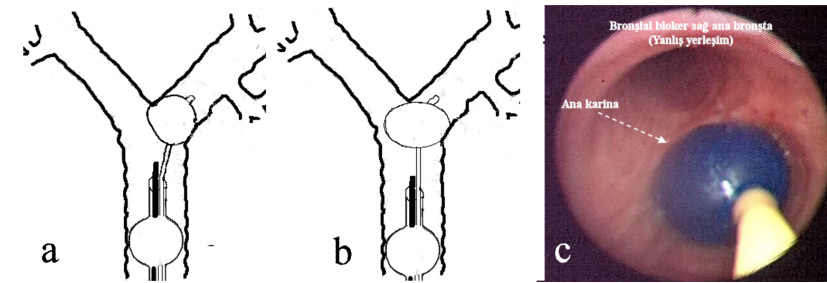
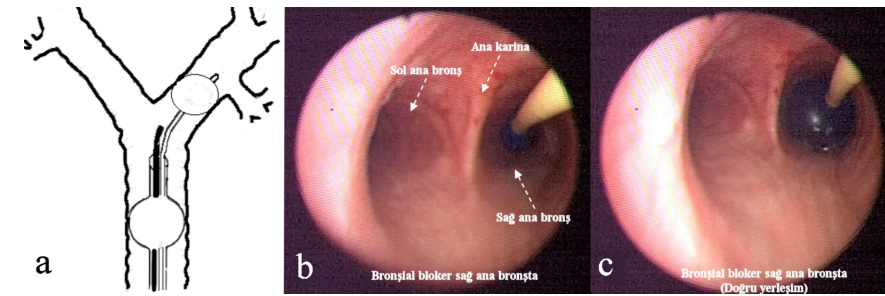
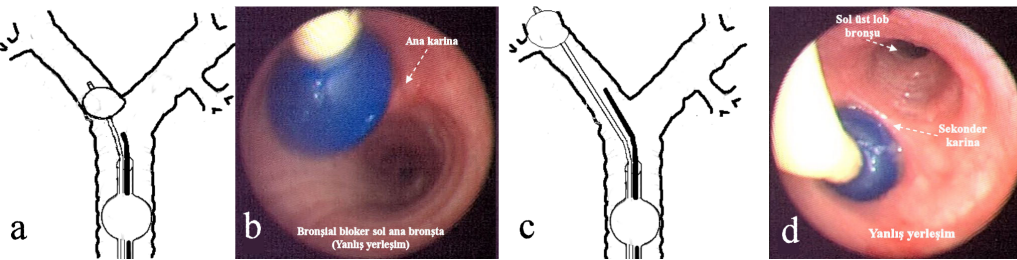
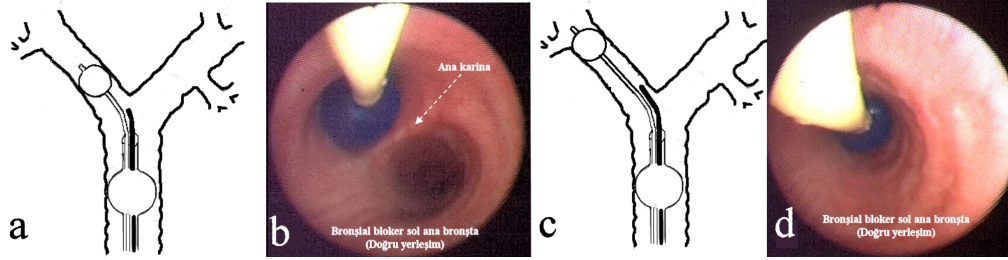
**One-lung ventilation using the
ProSeal™ laryngeal mask
airway**

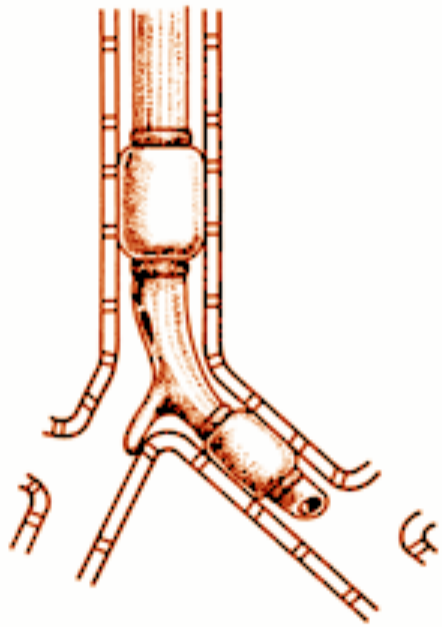
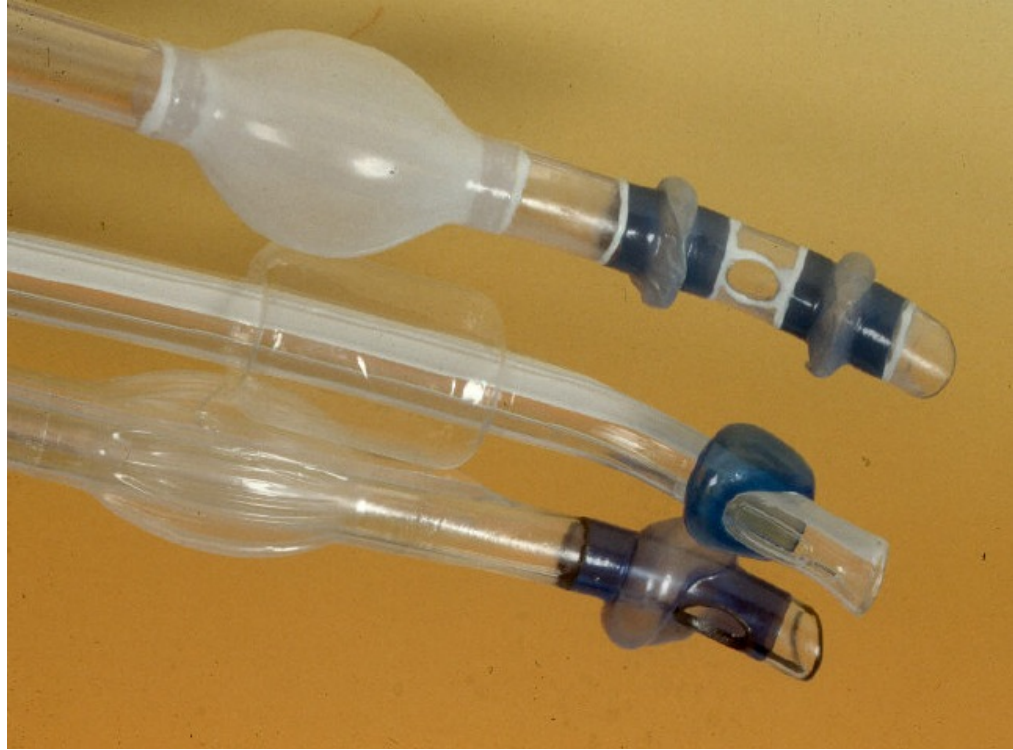
Anaesthesia, 2004, 59, pages 719–729



A Coopdech Bronchial Blocker catheter inserted in a ProSeal™ LMA.

Malpozisyonlar-BB





Sağ - sol ÇLT



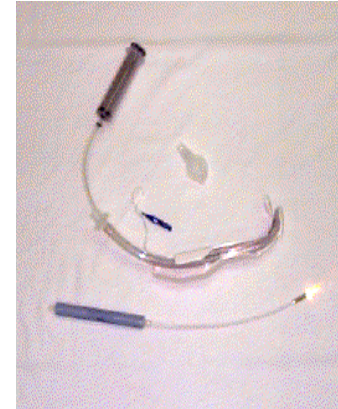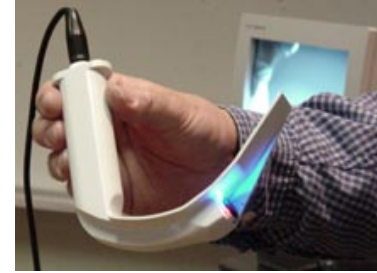- Sağ?
 - Sol ana bronşta lümen içi tm
 - İnen torasik aorta anevrizması-sol ana bronşa bası
 - Geçirilmiş cerrahi-sol trakeobronşiyal anatomide bozulma

Cinsiyet	Boy (cm)	Büyükük (Fr)
Kadın	< 160**	35
	> 160	37
Erkek	< 170***	39
	> 170	41

Tek lümenli tüpler		Çift lümenli tüpler			
İç çap (mm)	Dış çap (mm)	Büyükük (Fr)	Dış çap (mm)**	Bronşiyal iç çap (mm)	FOB çap (mm)***
6.5	8.9	26	8.7	3.2	2.4
7.0	9.5	28	9.3	3.4	2.4
8.0	10.8	32	10.7	3.5	2.4
8.5	11.4	35	11.7	4.3	≤ 3.5
9.0	12.1	37	12.3	4.5	≤ 3.5
9.5	12.8	39	13.0	4.9	≤ 3.5
10.0	13.5	41	13.7	5.4	≤ 3.5

Çift Lümenli Tüp

1. FOB
2. Videolarinoskoplar
3. Işıklı stile
4. Rijit Fiberoptik
laringoskoplar
Bullard, WuScope..
5. Tüp deęiřtirici



Use of lighted stylets to facilitate insertion of double-lumen endobronchial tubes in patients with difficult airway anatomy

Christopher J. O'Connor MD (Professor of Anesthesiology)^{a,*},
Thomas A. O'Connor MD (Chairman of Anesthesiology)^b

Journal of Clinical Anesthesia (2006) 18, 616–619

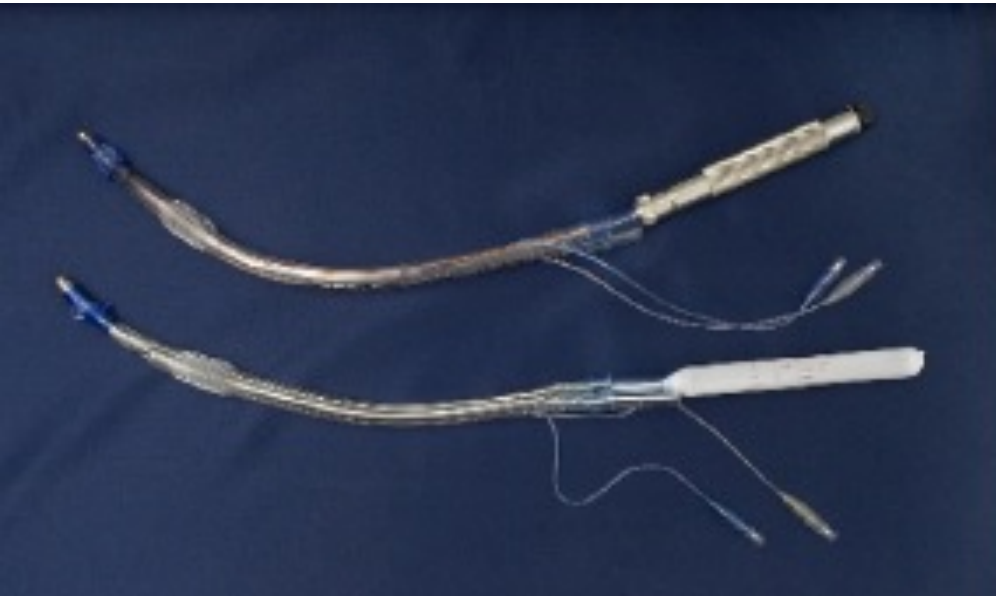


Table 1 Patient characteristics

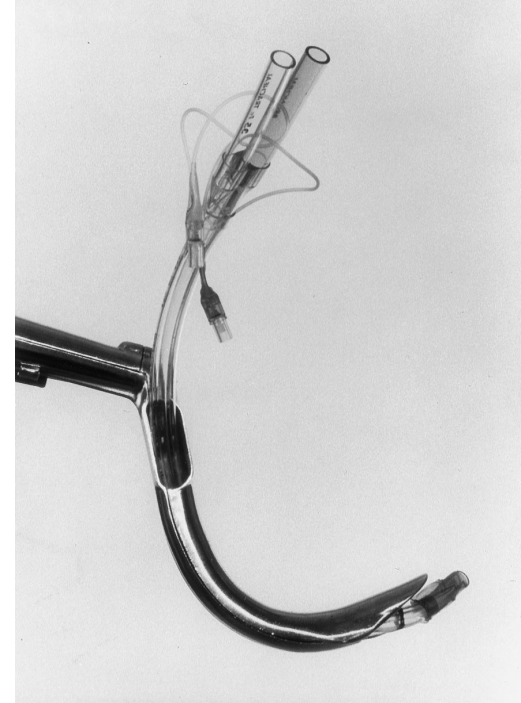
Patient	Procedure	Age/Gender	Height/Weight	Mallampati score	Airway features	DLT type	Success/Attempts	Esophageal intubations
1	Thoracoscopy, empyema drainage	65/M	183 cm/68 kg	II	Small mouth, prominent dentition	39 Fr left	Yes/1	None
2	Thoracoscopy, pleural effusion drainage	45/M	170 cm/67 kg	III	Narrow high-arched palate	37 Fr left	Yes/2	None
3	Thoracoscopy, lung biopsy	64/F	168 cm/84 kg	II	Small mouth, short TMD, full dentition	37 Fr left	Yes/1	None
4	Esophago-gastrectomy	42/F	173 cm/66 kg	II	Severe overbite	37 Fr left	Yes/1	None
5	Thoracotomy, pericardial cyst resection	44/M	173 cm/105 kg	I	Obese, limited neck extension	39 Fr right	Yes/1	None

M indicates male; F, female; TMD, thyromental distance.

Fiberoptic Laryngoscopy (WuScope) For Double-lumen Endobronchial Tube Placement in Two Difficult-intubation Patients

Anesthesiology
2000; 93:902

1. Motor kazası, entübe ve zorluk tanımlanmamış, servikal collar
 - Desc torasik aort laserasyon tamiri
 - ETT çıkarılıyor, 39 Fr, 37 Fr ve 35 Fr ÇLT deneniyor. 4. denemede Wu-Scope ile 35 Fr ÇLT başarılı.
2. Sağ alt torakotomi, AA 35 mm, Mallamp II, öne çıkık dişler
 - 37 Fr sol ÇLT ve Univent (No 7.0) ile ent başarısız (CL III), WuScope (CL I) ve 35 Fr sol ÇLT başarılı.



Insertion of the double lumen tube in the difficult airway

R. Satya-Krishna¹ and M. Popat²

Anaesthesia, 2006, 61, pages 896–898

- Sağ Ac torakotomi, çene augmentasyonu
- TMM kısa, Mallampati III, ağız tabanında operasyon skarı
- Uyanık FOB ile nazal entübasyon (RAE)
- FOB ile RAE yanından 35 Fr sol ÇLT ile oral entübasyon
- FOB çalışma kanalından kılavuz tel, ÇLT çıkarılır, FOB ile nazotrakeal RAE

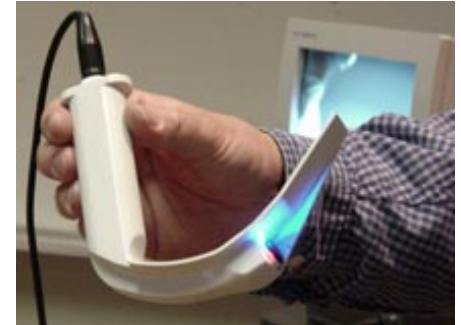

GlideScope-Assisted Double-Lumen Endobronchial Tube Placement in a Patient With an Unanticipated Difficult Airway

J Cardiothorac Vasc Anesth 2008;22:170-172.

Albert Chen, MD
Hsien-Yong Lai, MD, PhD
Pei-Chin Lin, MD
Tsung-Ying Chen, MD
Ming-Hwang Shyr, MD, PhD
Department of Anesthesiology
General Hospital and University
Hualien, Taiwan

- Torasik vertebra dekompresyonu
- Preop havayolu normal.
- Mac #3 ile 35 Fr sol ÇLT yerleştirilmesi başarısız.
- Glidescope ile 35 Fr ÇLT, 2 kere deneniyor ve başarısız
- Glidescope ve stile ile tek lümenli tüp başarılı
- 14 F tüp değiştirici ile ÇLT Glidescope yardımıyla glottisten geçiriliyor.
- Sola yerleşim FOB ile kontrol



The Airway Scope for difficult double tube intubation

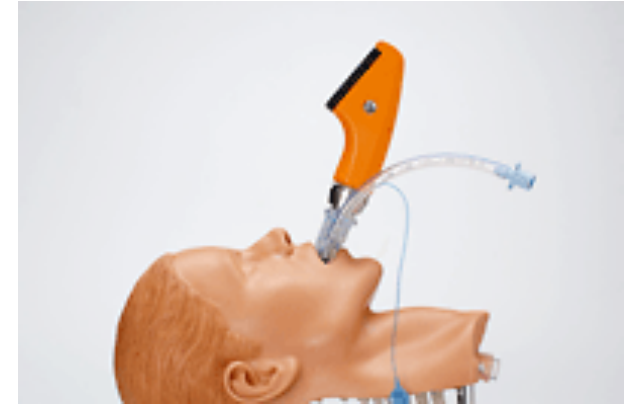Journal of Clinical Anesthesia (2008) 20, 319

K.H. Poon MMed
(Consultant)

Eugene H.C. Liu MPhil, FRCA
(Senior Consultant)

Department of Anaesthesia, National University of Singapore

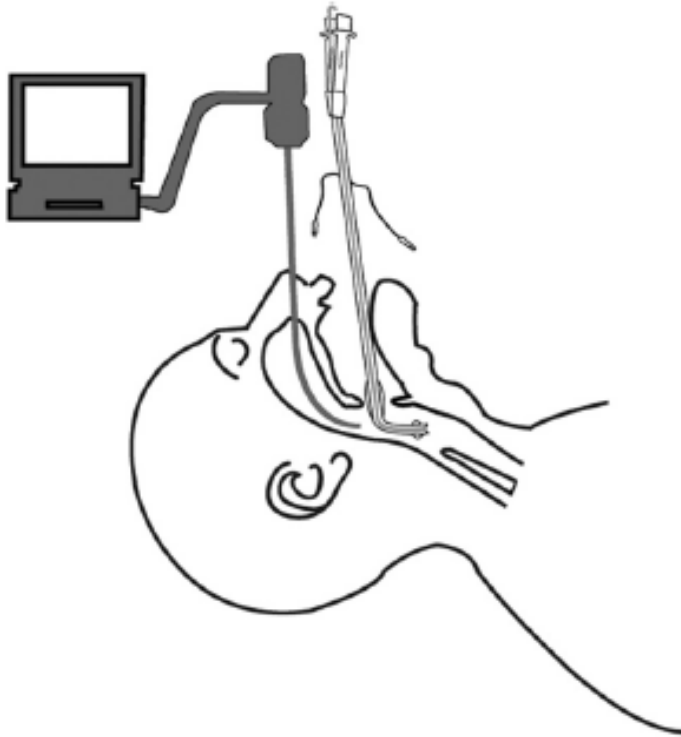
1. Macintosh ile CL III Airway Scope ile CL I. SLT ve tüp deęiřtirici ile 37 Fr ÇLT
2. Macintosh ile CL III, gum elastik buji ile entb başarısız. Airway Scope ile CL I ve gum elastik buji üzerinden 37 Fr ÇLT yerleřtiriliyor.



Use of a video fiberoptic bronchoscope to assist double-lumen endobronchial tube intubation in a patient with a difficult airway

Kuan-Yu Chen. Shih-Kai Lin. Chia-Liang Hsiao. Wei-Ti Hsu. Shao-Lun Tsao*

Acta Anaesthesiologica Taiwanica 49 (2011) 26–28



- Ağız içi cerrahi, radyoterapi AA:2 cm, sert boyun, ekstansiyon sınırlı
- 35 Fr ÇLT, oral FOB ile uyanık entübasyon, başarısız
- ÇLT' nin stilesi hokey sopası gibi kıvrılarak, video FOB ile vokal kordlardan geçirilebiliyor.

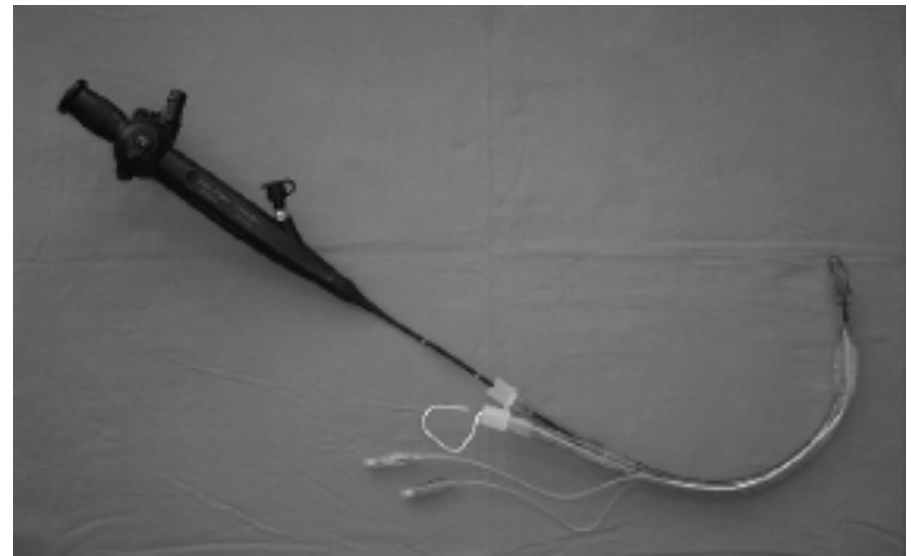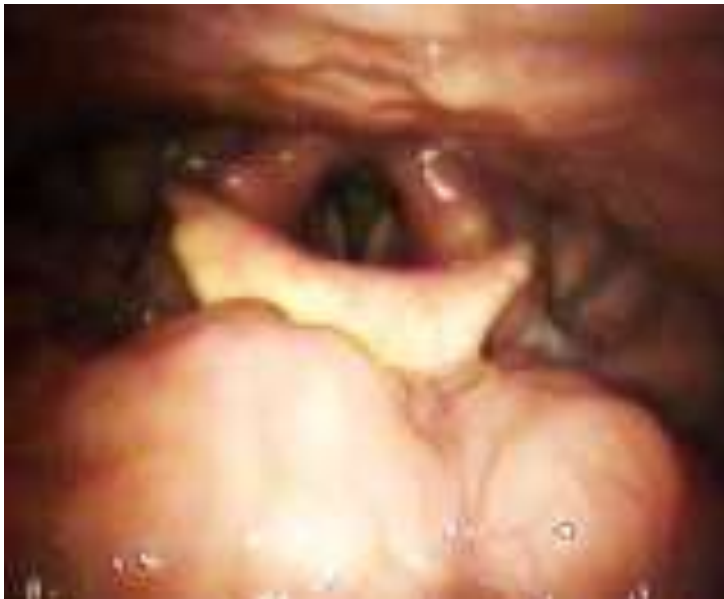Unexpected difficult intubation due to lingual tonsillar hyperplasia in a thoracotomy patient: intubation with the double-lumen tube using stylet and fiberoptic bronchoscopy

Mehmet E. Orhan MD
Alper Gözübüyük MD
Ali Sızlan MD
Umur Dere MD

Journal of Clinical Anesthesia (2009) 21, 439–441

^aDepartment of Anesthesiology, Gülhane Military Medical Academy School of Medicine, Ankara, Turkey

^bDepartment of Thoracic Surgery, Gülhane Military Medical Academy School of Medicine, Ankara, Turkey

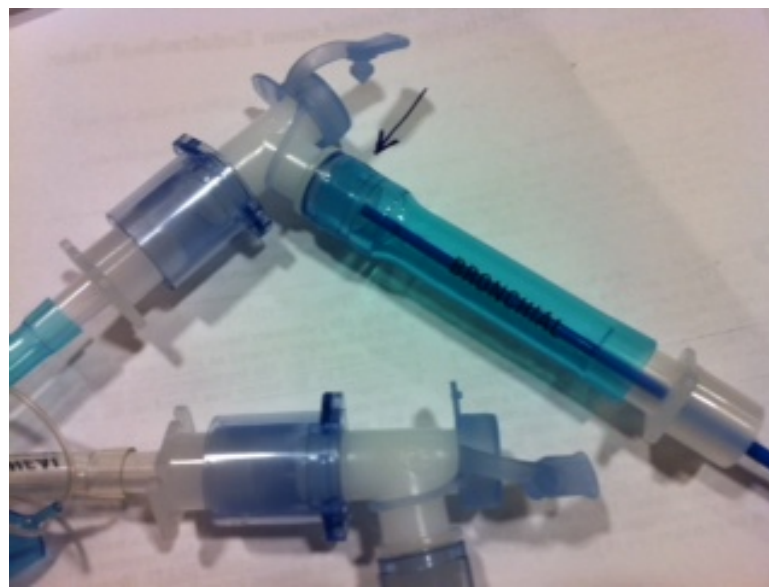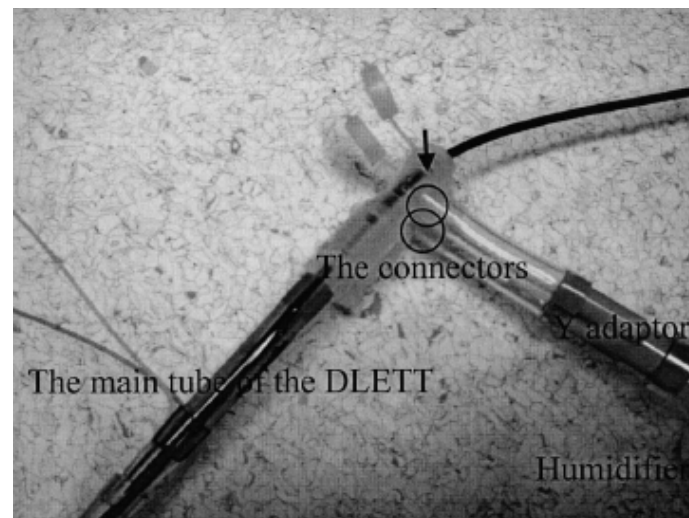



- İmalat hataları!!
- Uygulama hataları
- Kullanım öncesi ve sonrasında kontrol

Difficult Ventilation with a Double-Lumen Endotracheal Tube: An Unusual Manufacturing Defect

Anesth Analg 2005;101:1094-7

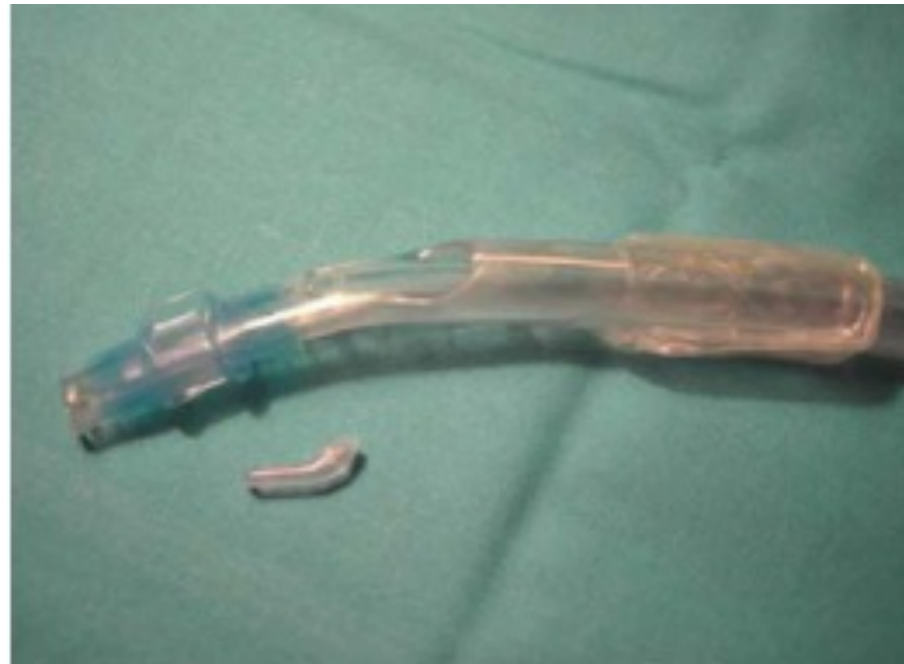Hung-Shu Chen, MD, Bruno Jawan, MD, Chia-Chih Tseng, MD, Kwok-Wai Cheng, MD, and Chih-Hsien Wang, MD



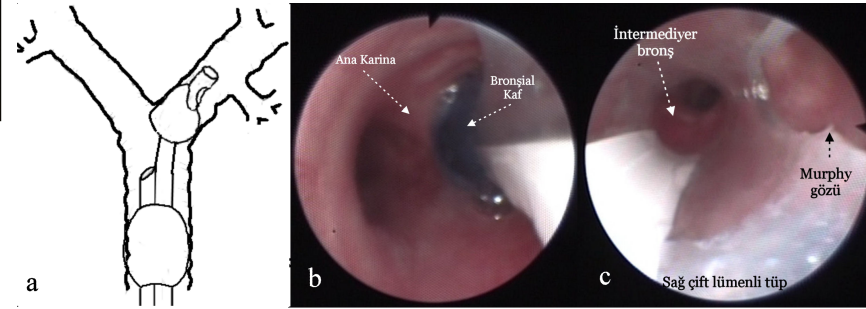
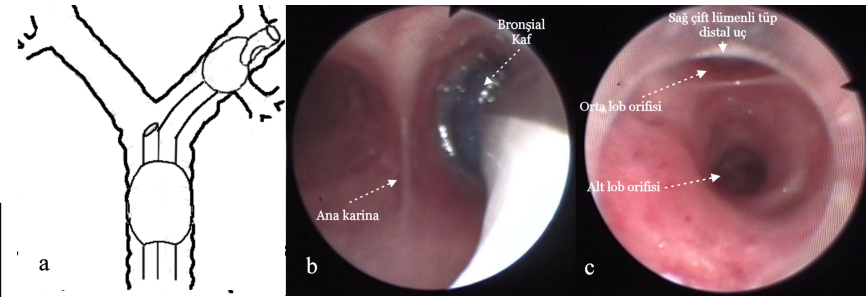
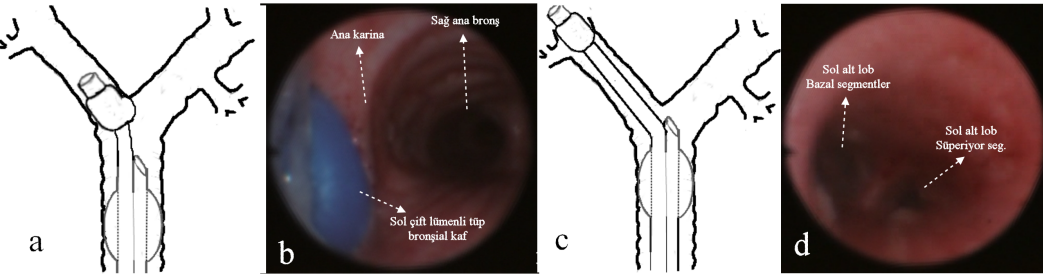
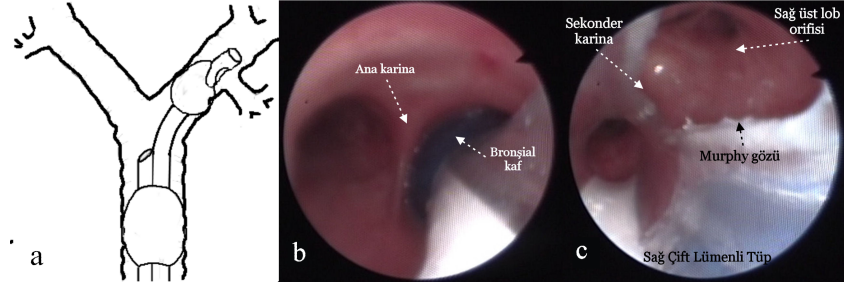
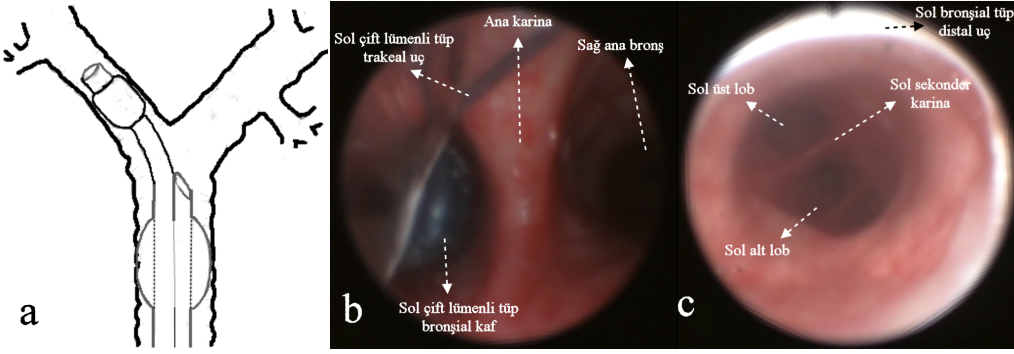
“Detachment of the carinal hook following endobronchial intubation with a double lumen tube”

Rocha *et al.* *BMC Anesthesiology* 2011, **11**:20

Ana C Rocha^{1,2*}, Mafalda G Martins¹, Luísa I Silva¹ and José M Nunes¹



Malpozisyonlar-ÇLT



Tek Akciğer Ventilasyonunda Çift Lümenli Tüp ile Bronşiyal Blokerin Karşılaştırılması

Comparison of Double Lumen Tube with
Bronchial Blocker in One Lung Ventilation

Dr. Alparslan KUŞ,^a
Dr. Tülay ŞAHİN YILDIZ,^a
Dr. Mine SOLAK,^a
Dr. Kamil TOKER^a

^aAnesteziyoloji ve Reanimasyon AD,
Kocaeli Üniversitesi Tıp Fakültesi,
Kocaeli

Malpozisyon tipleri.

	Grup ÇLT (n= 20)	Grup BB (n= 20)
Bronş kafının trakeaya herniasyonu	1	9
Bronş kafının aşırı ileri gitmesi	3	-
Yetersiz akciğer izolasyonu	-	1

Unusual case of difficult double-lumen endotracheal tube removal

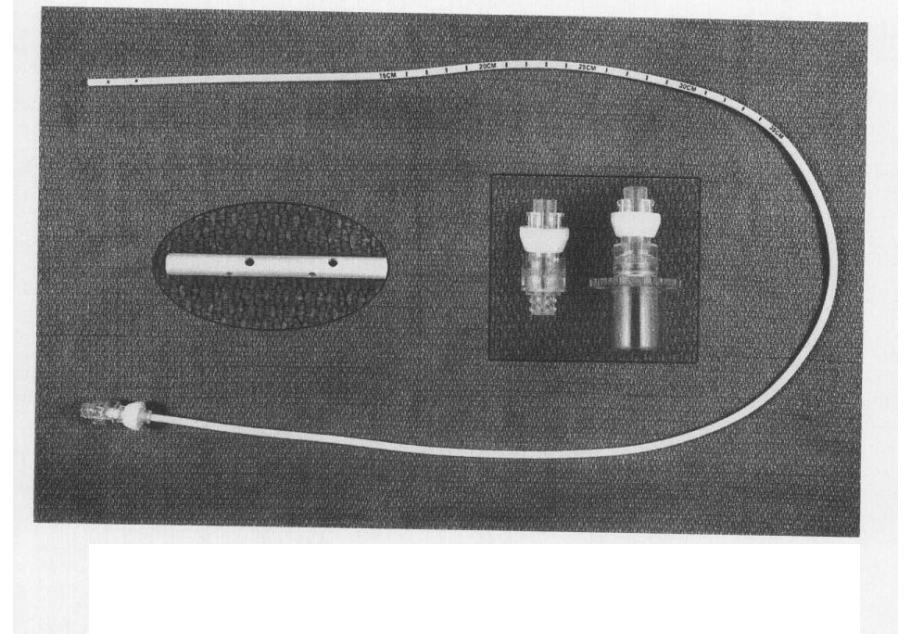
Journal of Clinical Anesthesia (2009) 21, 514–516

Vanda G. Yazbek-Karam MD

- Atopi öyküsü, 37 Fr reusable sol Robertshaw ÇLT
- Başarısız TAV, 5 dk sonra sadece 2-3 cm geri çekilebiliyor.
- Göğüs grafisi-bronşiyal kaf karina seviyesinde sol ana bronşta, trakeal kaf krikoid kıkırdak hizasında
- Yaygın havayolu ödemi
- 48 saat sonra CT de minimal ödem
- Tüp değiştirici ile ÇLT çıkarılabiliyor
- ÇLT- uç kısmı 13.5 mm, trakeal kaf hizasında ise 15.5 mm.
- 6.5 no ETT ile kolaylıkla entübe ediliyor.
- Latex allerjisi için- Serum triptaz ve IgE negatif.

Tüp Deęiřtiriciler

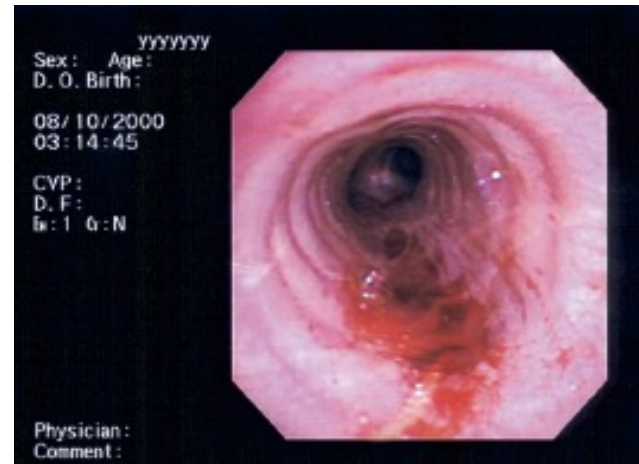- LT iin min 83 cm
- Dudak hizasından maks. 24 cm
- Sniffing pozisyonu
- Deęiřim sırasında laringoskop kullanımı ile başarı oranı %22 vs %74



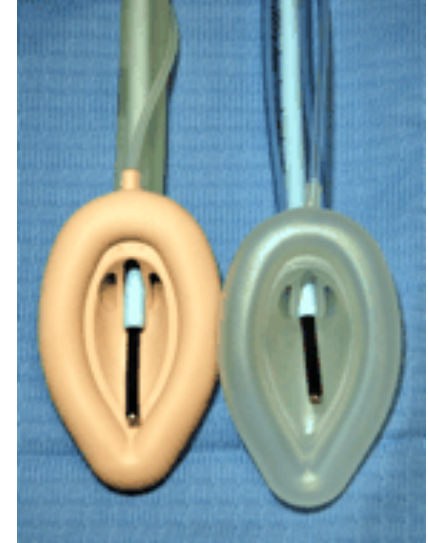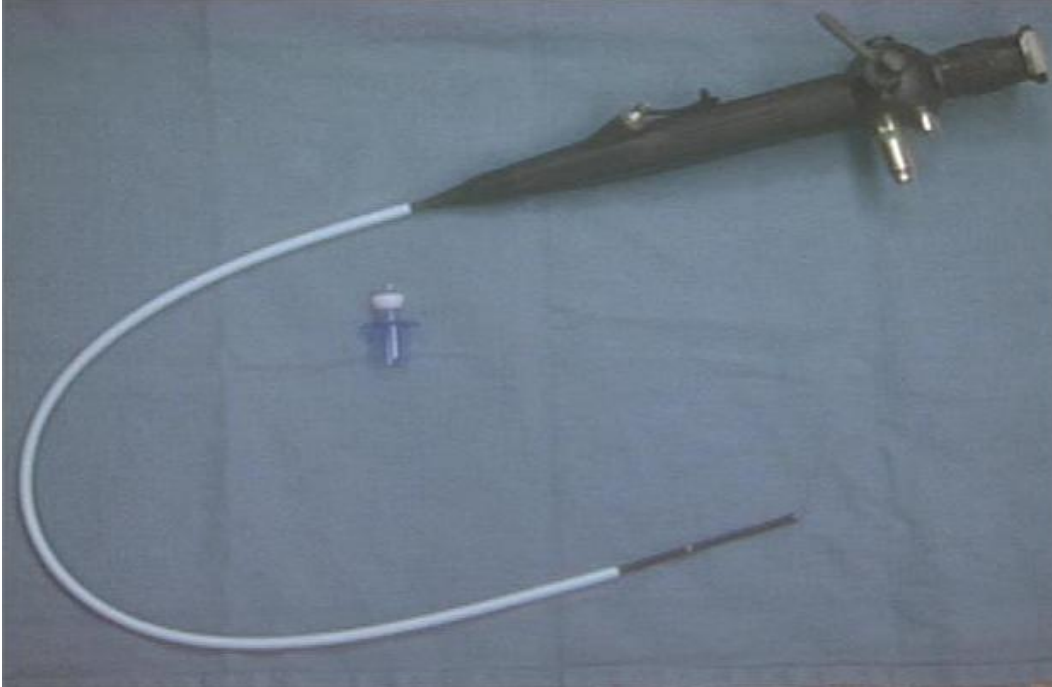Tracheal Laceration After the Use of an Airway Exchange Catheter for Double-Lumen Tube Placement

Vinoo Thomas, MD, and Steven M. Neustein, MD

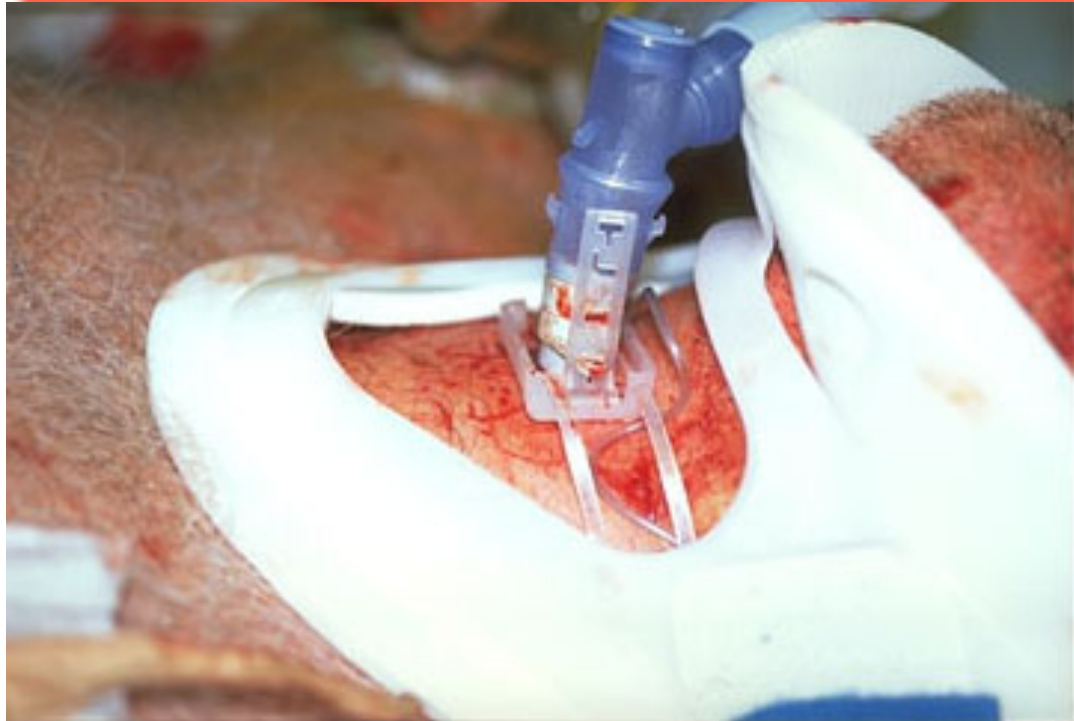Journal of Cardiothoracic and Vascular Anesthesia, Vol 21, No 5 (October), 2007: pp 718-719



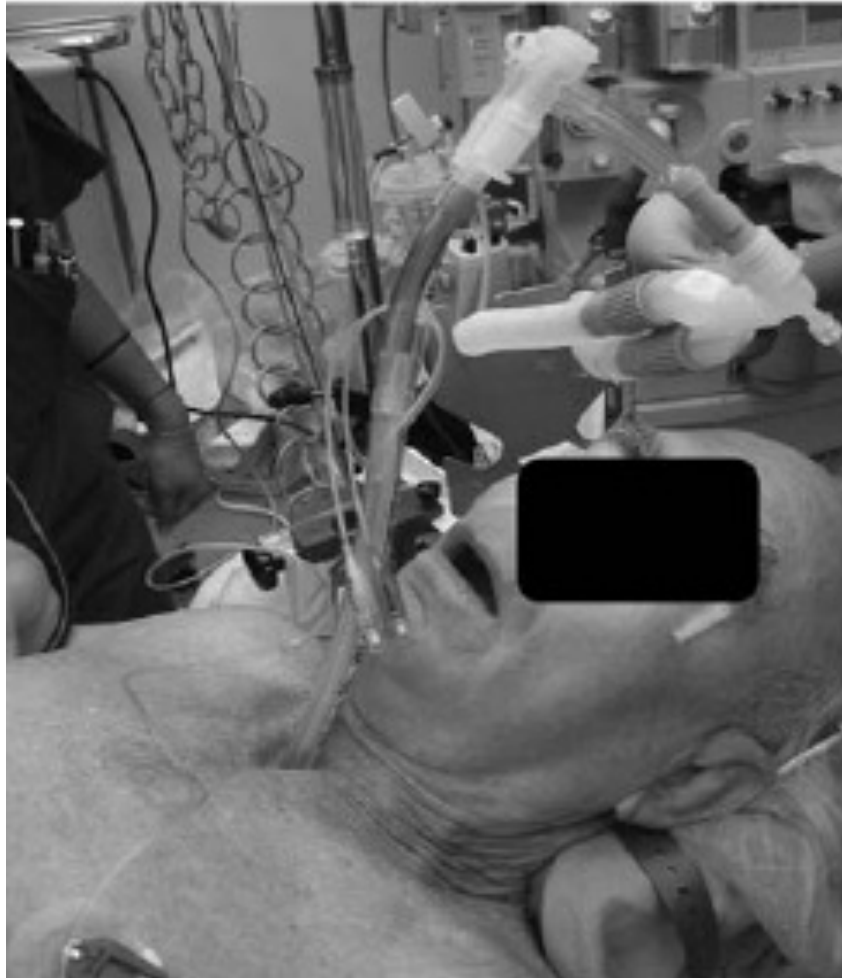Aintree Entübasyon Kateteri



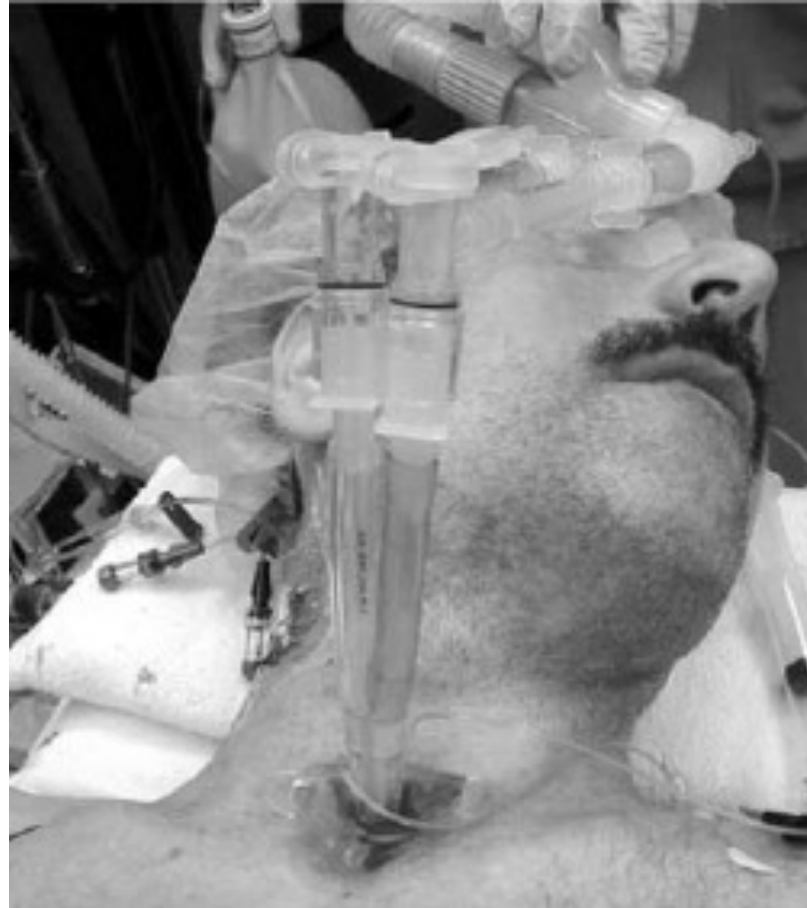TRAKEOSTOMİZE HASTA



ÇLT



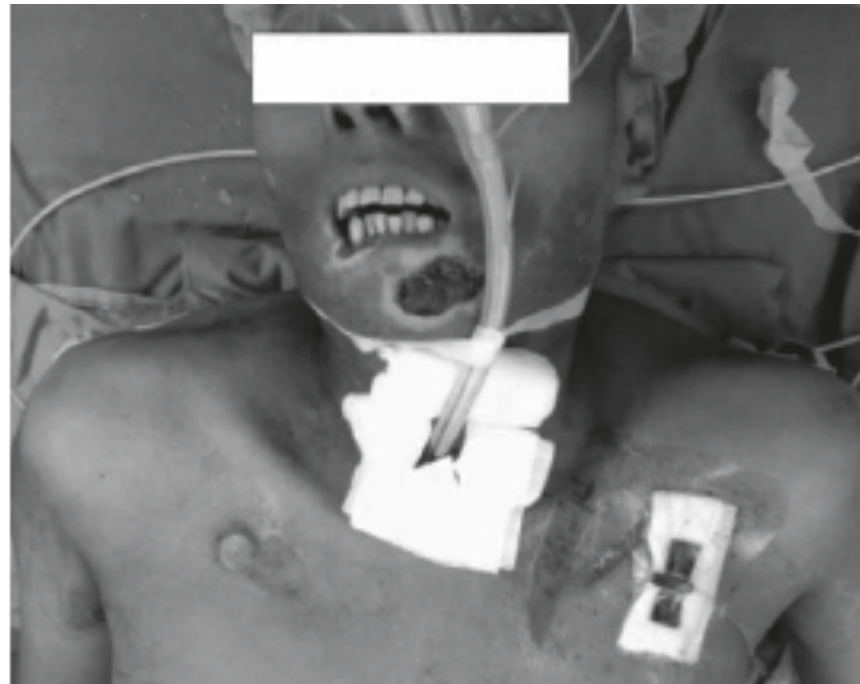Kısa ÇLT (Naruke)

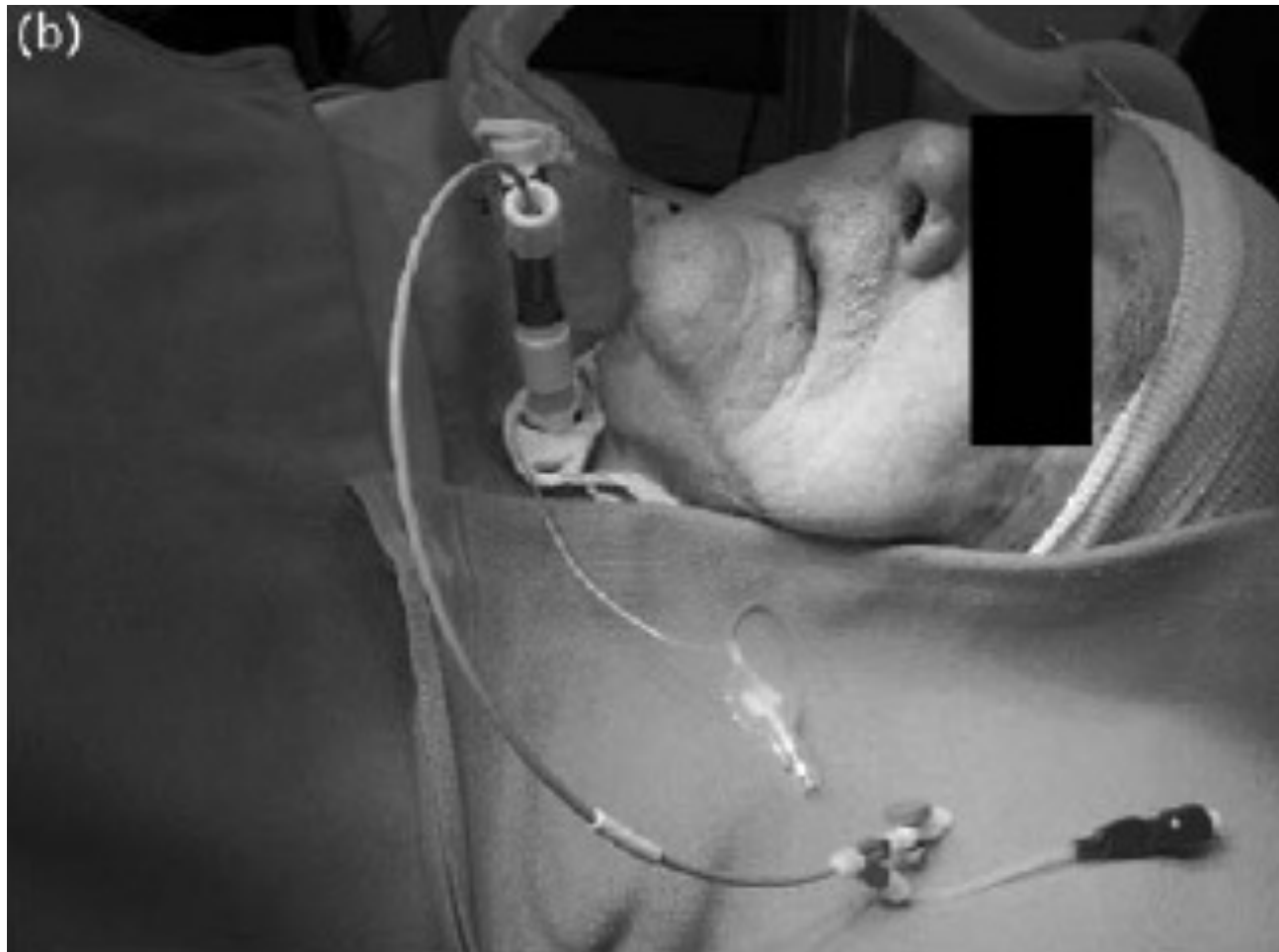


Application of a Double-lumen Tube for One-lung Ventilation in Patients With Anticipated Difficult Airway

Acta Anaesthesiol Taiwan 2010;48(1):41-44

Chih-Kai Shih, Yi-Wei Kuo, I-Chen Lu, Hong-Te Hsu, Koung-Shing Chu, Fu-Yuan Wang*

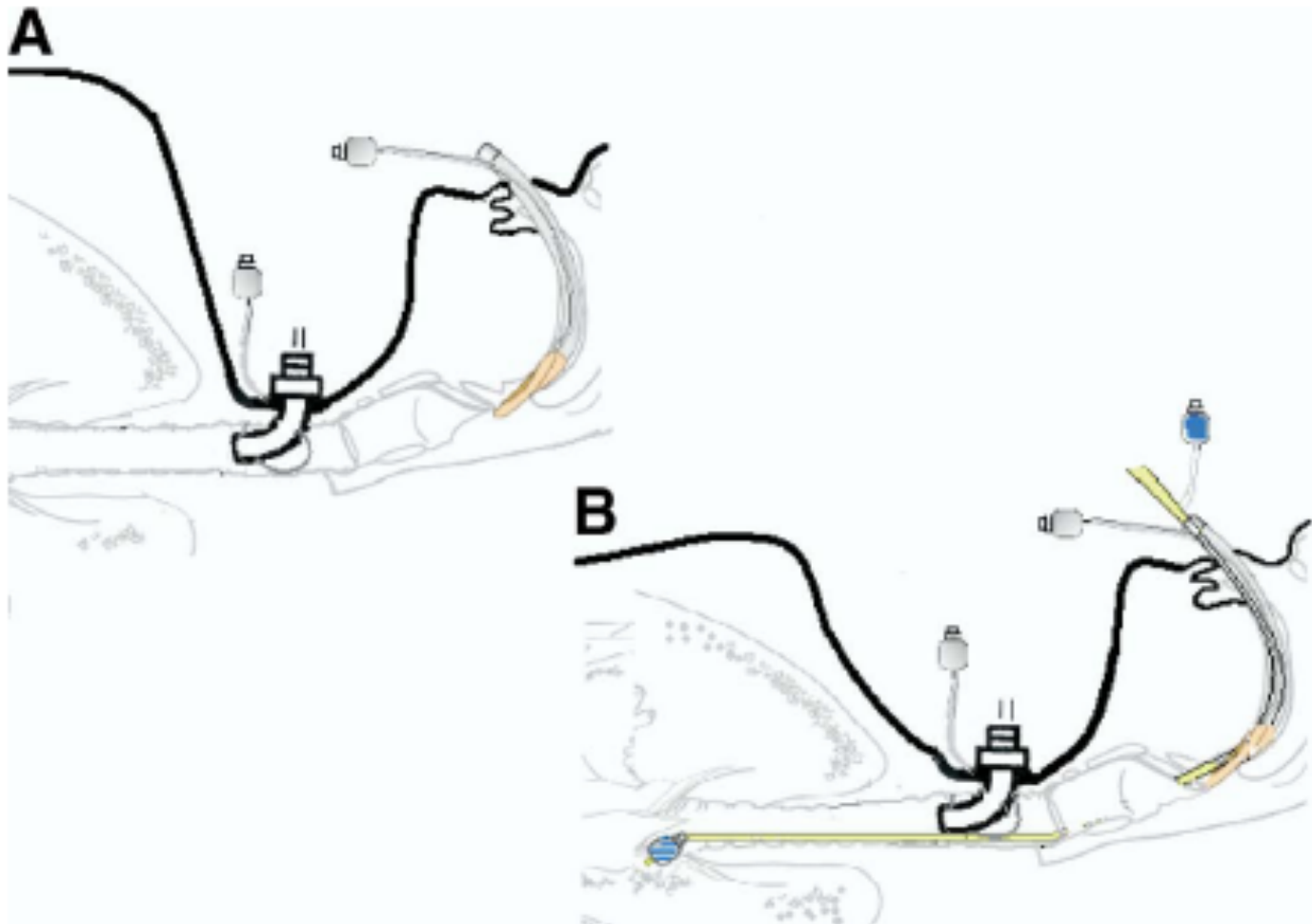




Lung Isolation Using a Laryngeal Mask Airway and a Bronchial Blocker in a Patient With a Recent Tracheostomy

Albert R. Robinson III, MD,* Nikolaus Gravenstein, MD,*† Estibaliz Alomar-Melero, MD,*
and Yong G. Peng, MD*‡

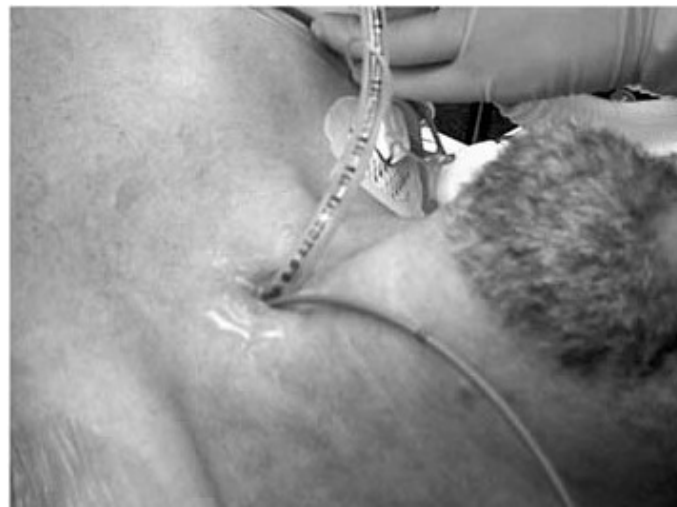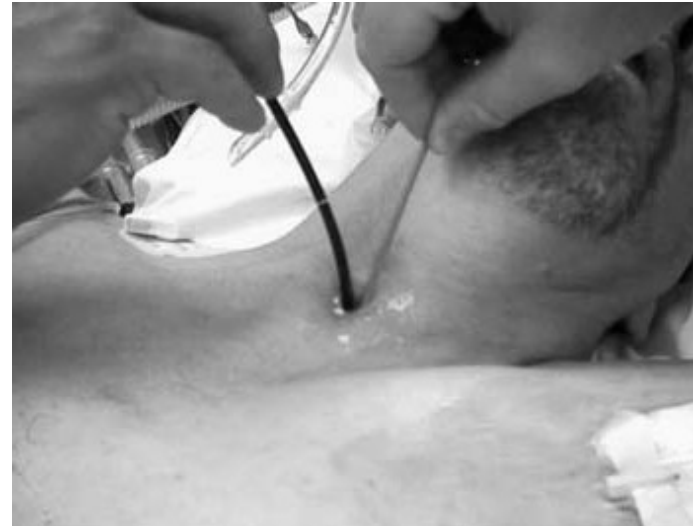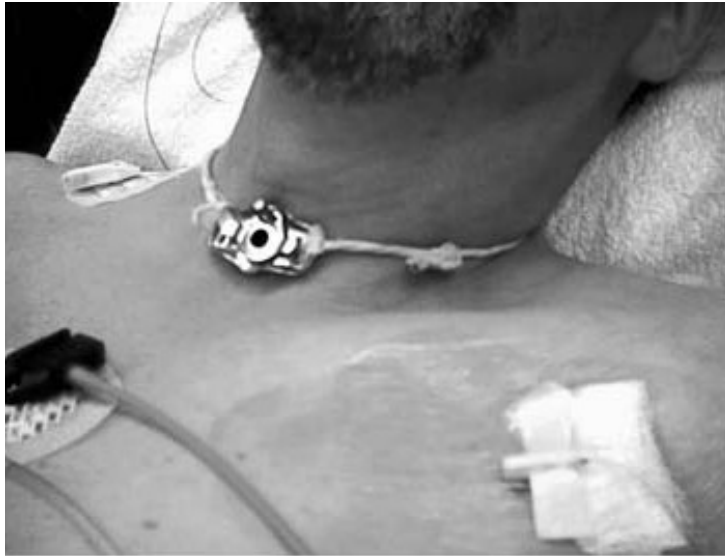Journal of Cardiothoracic and Vascular Anesthesia, Vol 22, No 6 (December), 2008: pp 883-886

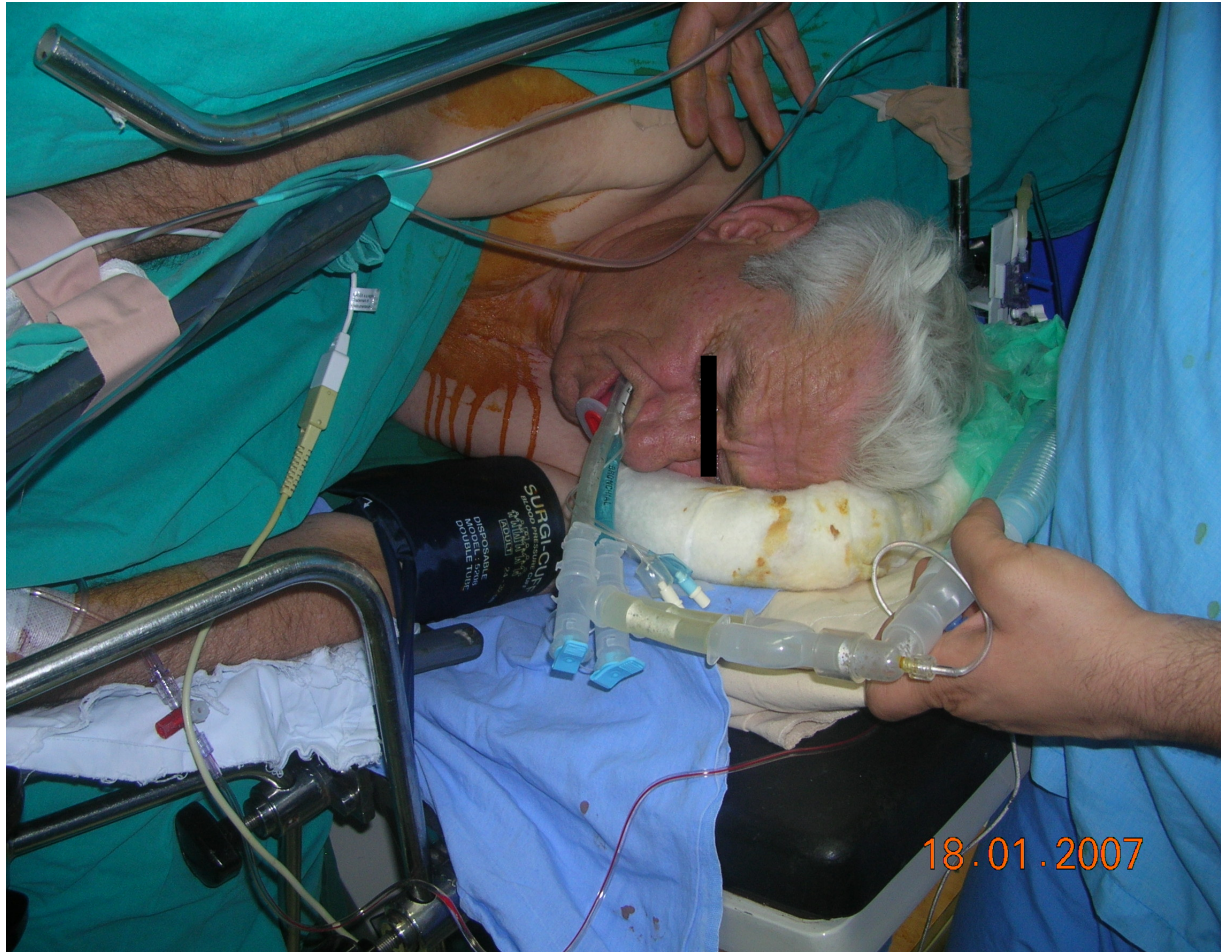

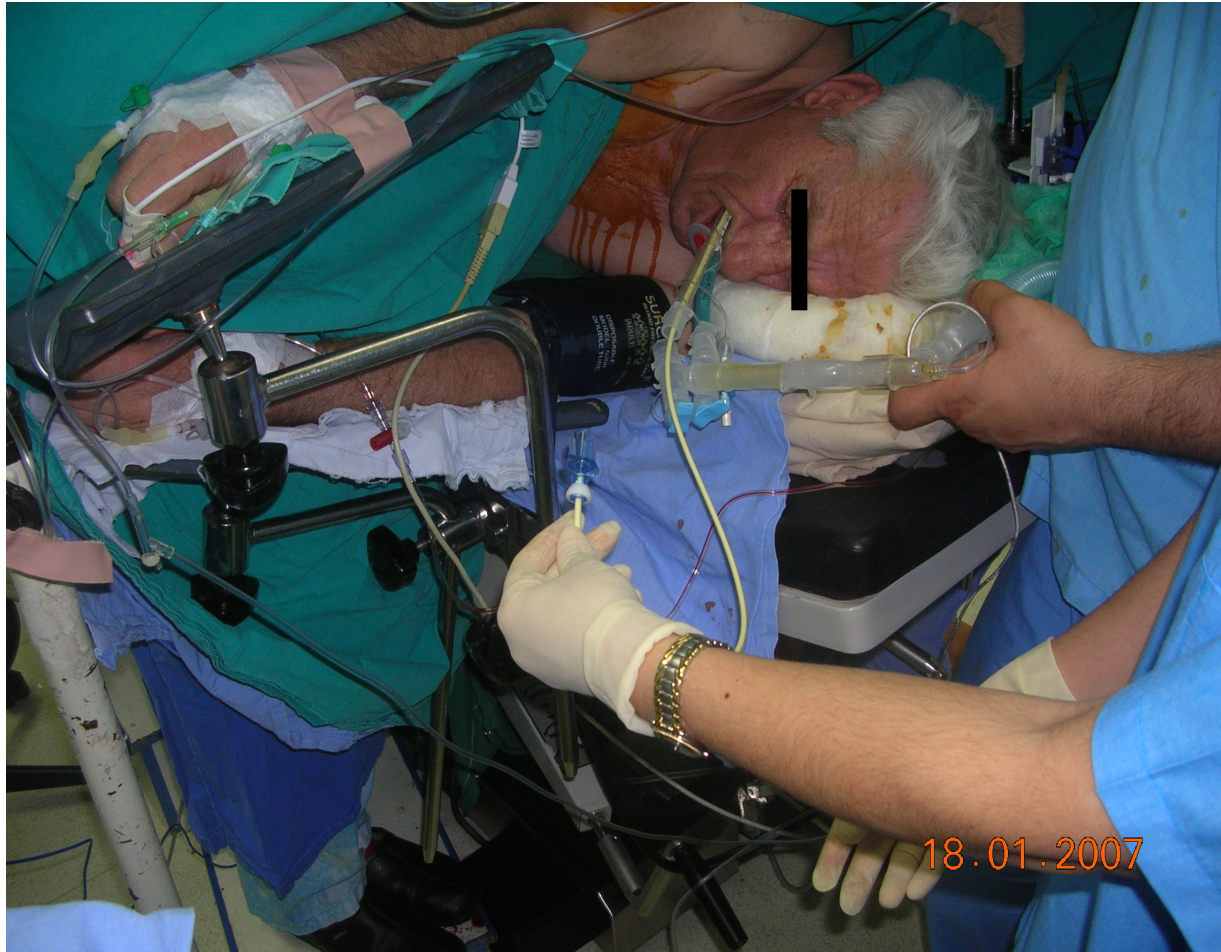
Lung separation and the difficult airway

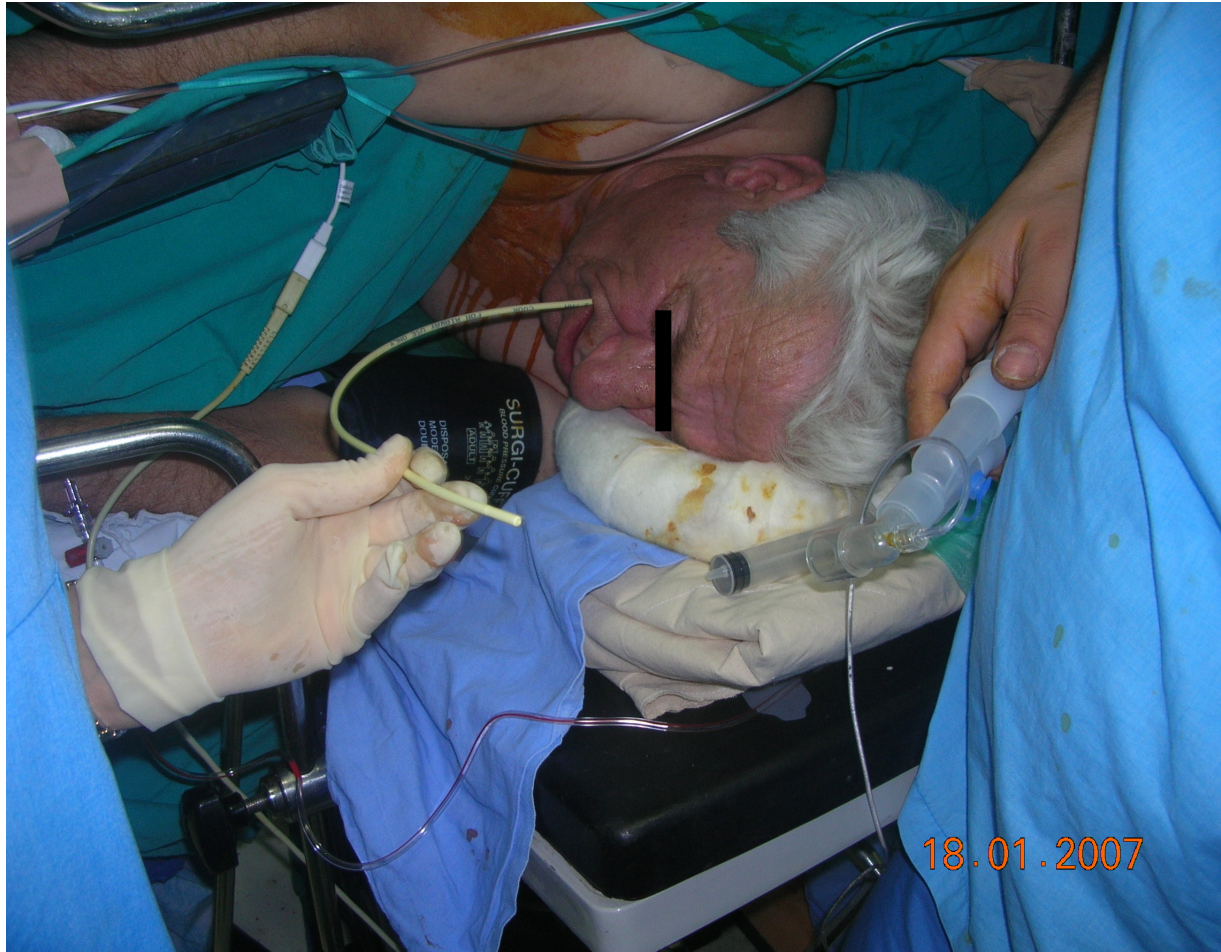British Journal of Anaesthesia 103 (BJA/PGA Supplement): i66–i75 (2009)

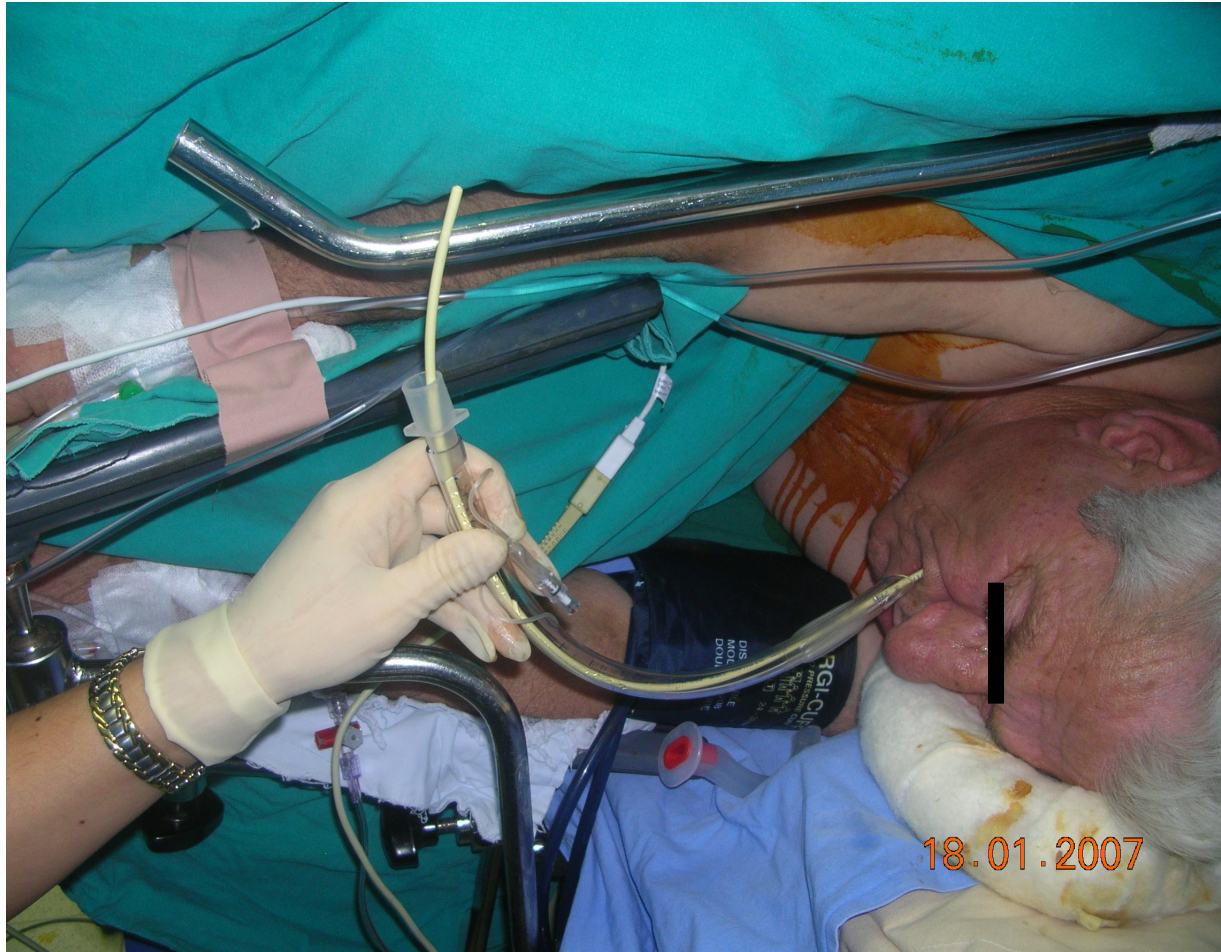
J. B. Brodsky*

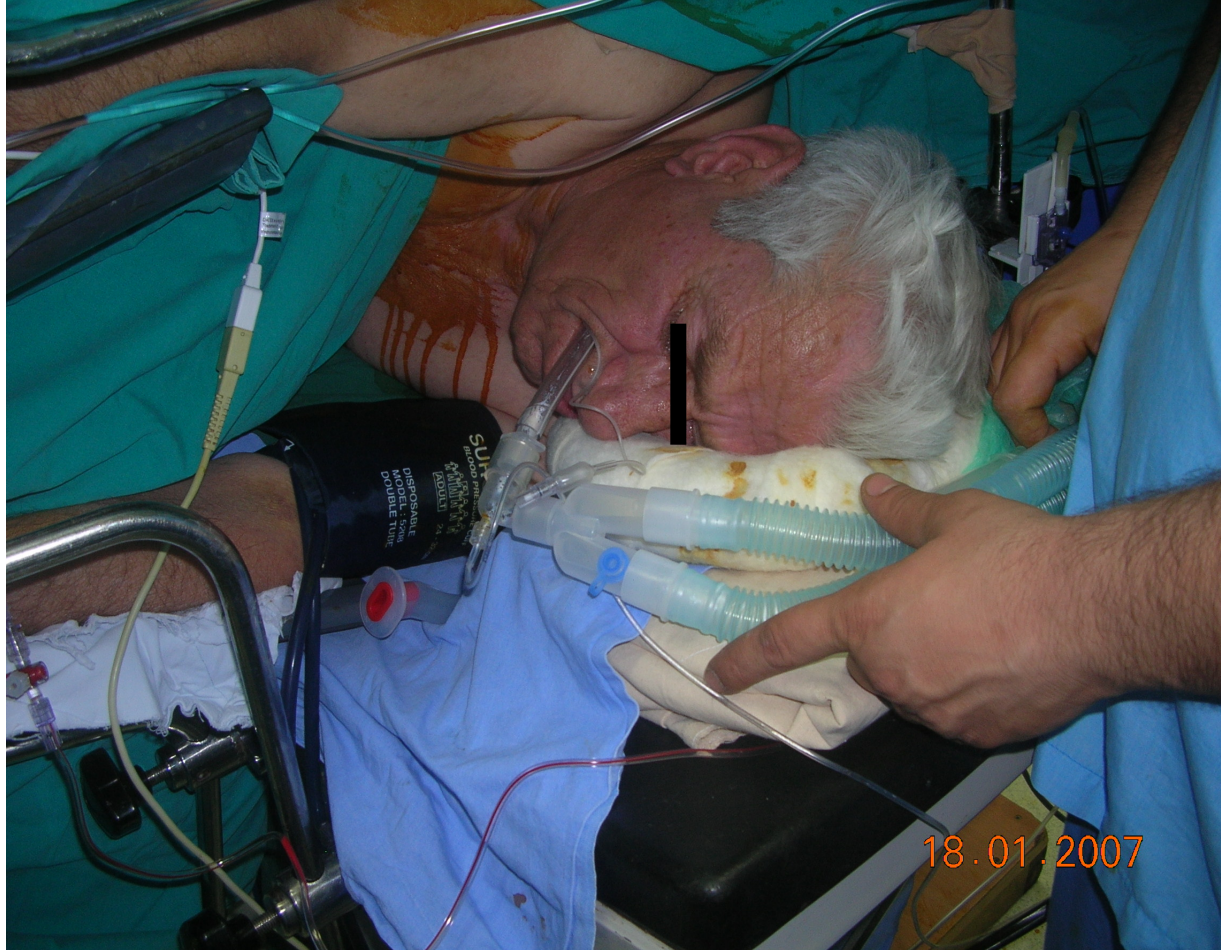

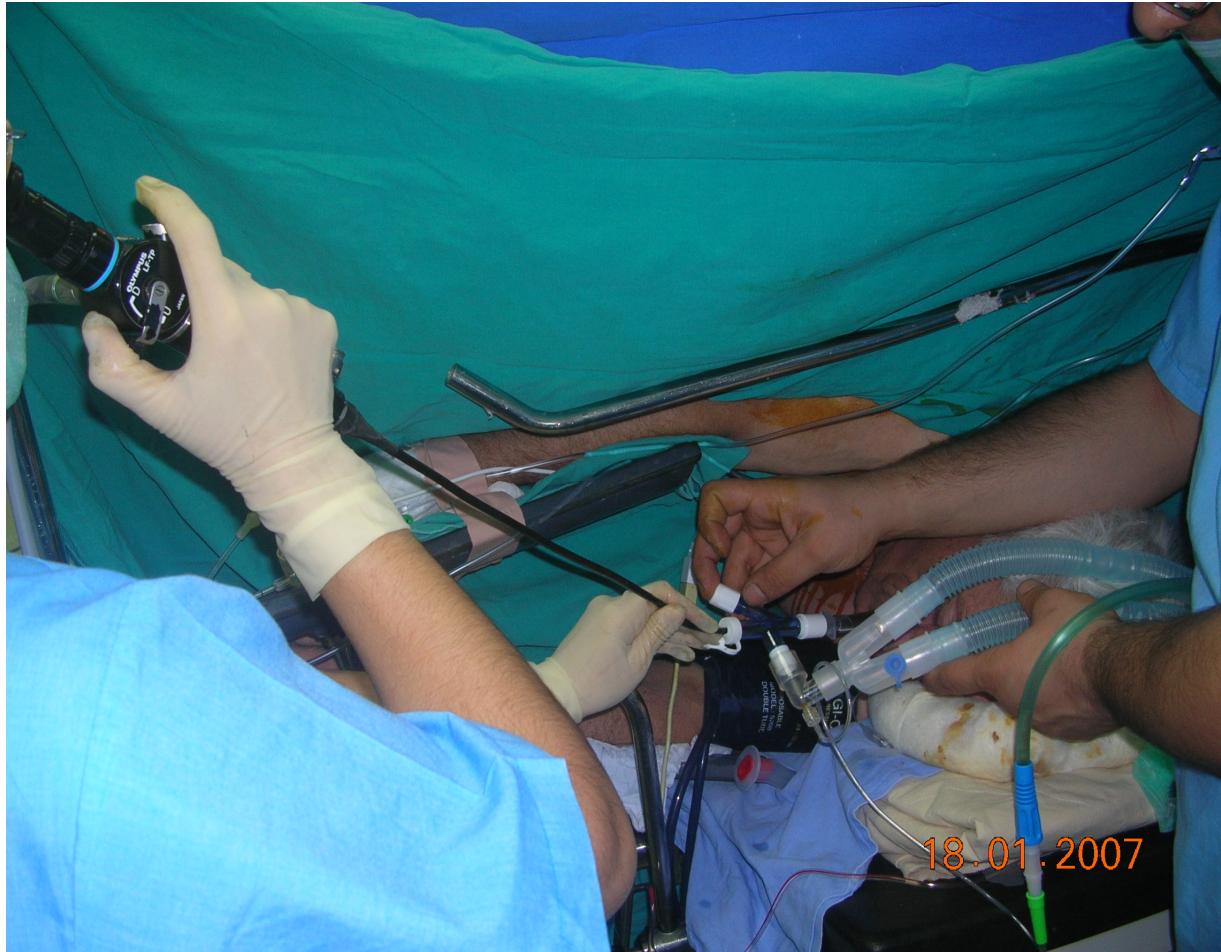



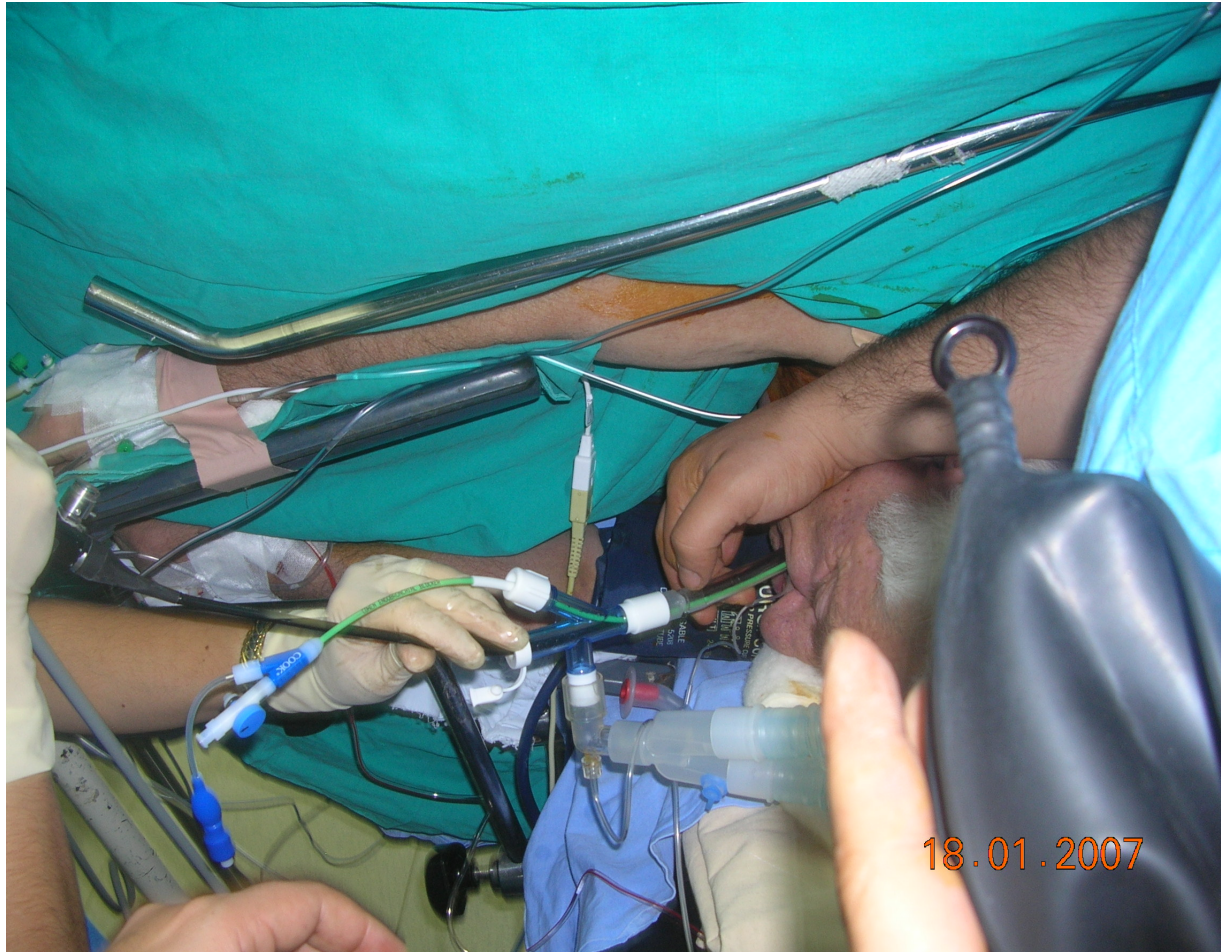


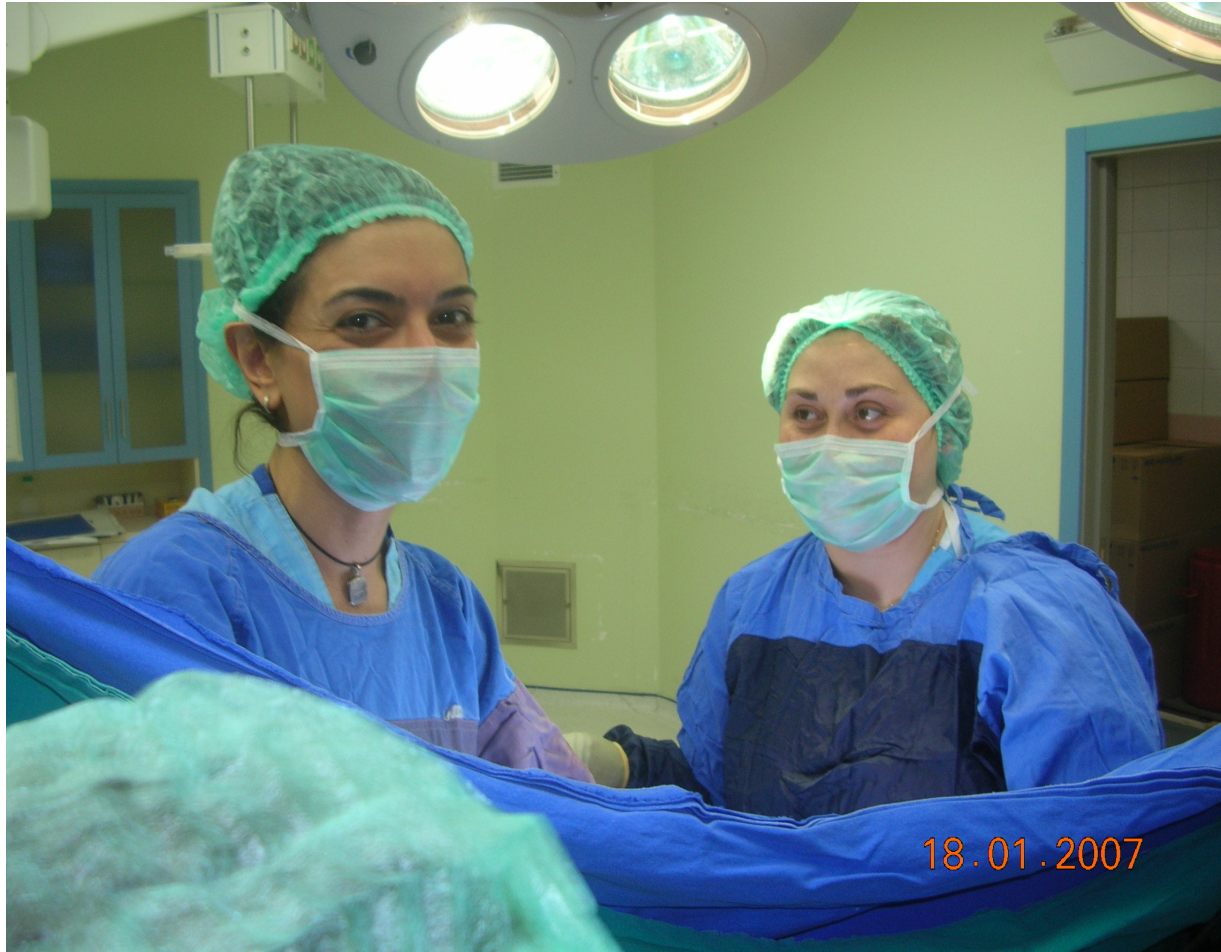











Sabrınız ve dikkatiniz için teşekkürler..